

27-6-2024

Diabetic foot ulcer treated with the homoeopathic medicine Lachesis mutus in millesimal potencies: A case report

Lalith Singh

National Institute of Homoeopathy, Kolkata, West Bengal, India, drlalithsingh@gmail.com

Raja Manoharan

National Institute of Homoeopathy, Kolkata, West Bengal, India, drrajanih@gmail.com

Niharika Shaw

National Institute of Homoeopathy, Kolkata, West Bengal, India, drniharikashaw@gmail.com

Saleem Ansari

National Institute of Homoeopathy, Kolkata, West Bengal, India, saleemgalib93@gmail.com

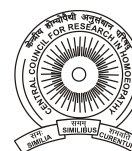Follow this and additional works at: <https://www.ijrh.org/journal>

 Part of the [Homeopathy Commons](#)

How to cite this article

Singh L, Manoharan R, Shaw N, Ansari S. Diabetic foot ulcer treated with the homoeopathic medicine Lachesis mutus in millesimal potencies: A case report. Indian J Res Homoeopathy 2024;18:147-153.

This Case Report is brought to you for free and open access by Indian Journal of Research in Homoeopathy. It has been accepted for inclusion in Indian Journal of Research in Homoeopathy by an authorized editor of Indian Journal of Research in Homoeopathy. For more information, please contact ijrhonline@gmail.com.



Diabetic foot ulcer treated with the homoeopathic medicine *Lachesis mutus* in millesimal potencies: A case report

Abstract

Introduction: Diabetic foot ulcer (DFU) is the most common neuropathic complication of diabetes. Uncontrolled diabetes and improper foot care lead to serious conditions like DFU from minor injuries. Regular dressing and proper foot care are required for its improvement. Patients are left with no other option than amputation of the limb. Dressing for a longer period seems not convenient and feasible at the patient's end. DFU also has wet gangrene as one of its major complications. **Case Summary:** This case report presents a case of a diabetic patient complaining of a foot ulcer for the past nine years, following the bite of a mongoose. On the basis of totality of symptoms, individualised homoeopathic medicine *Lachesis mutus* was prescribed. The ulcer improved in three months after homoeopathic medication without the use of any external application. The improvement has been depicted in this case report through pictographic evidence. The subjective assessment of the case was done using Outcomes Related to Impact on Daily Living (ORIDL) and Modified Naranjo Criteria for Homoeopathy (MONARCH) was used to evaluate the causal-effect relationship in the case, which showed a score of +3 and +8, respectively. The improvement in the ulcer was also assessed through photographs.

Acknowledgments and Source of Funding

NIL

Diabetic foot ulcer treated with the homoeopathic medicine *Lachesis mutus* in millesimal potencies: A case report

Lalith Singh, Raja Manoharan, Niharika Shaw*, Saleem Ansari
National Institute of Homoeopathy, Kolkata, West Bengal, India

Abstract

Introduction: Diabetic foot ulcer (DFU) is the most common neuropathic complication of diabetes. Uncontrolled diabetes and improper foot care lead to serious conditions like DFU from minor injuries. Regular dressing and proper foot care are required for its improvement. Patients are left with no other option than amputation of the limb. Dressing for a longer period seems not convenient and feasible at the patient's end. DFU also has wet gangrene as one of its major complications. **Case Summary:** This case report presents a case of a diabetic patient complaining of a foot ulcer for the past nine years, following the bite of a mongoose. On the basis of totality of symptoms, individualised homoeopathic medicine *Lachesis mutus* was prescribed. The ulcer improved in three months after homoeopathic medication without the use of any external application. The improvement has been depicted in this case report through pictographic evidence. The subjective assessment of the case was done using Outcomes Related to Impact on Daily Living (ORIDL) and Modified Naranjo Criteria for Homoeopathy (MONARCH) was used to evaluate the causal-effect relationship in the case, which showed a score of +3 and +8, respectively. The improvement in the ulcer was also assessed through photographs.

Keywords: Diabetes mellitus, Diabetic foot ulcer, Homoeopathy, *Lachesis mutus*

INTRODUCTION

Diabetes mellitus (DM) is one of the most common metabolic disorders around the globe with a high prevalence in western countries and increasing incidence in Asian countries, including India. According to a recent report by the National NCD Monitoring Survey, diabetes prevalence in India stood at 9.3% in 2018. Similar estimates have been given by International Diabetes Federation (IDF), where diabetes prevalence was estimated at 9.6% in 2021 and is projected to increase to 10.4% by 2030.^[1] Diabetic foot ulcer (DFU) is one of the common problems in poorly controlled or uncontrolled diabetes.^[2] Among all complications, the risk of DFU is 19–34% and this number is rising with the increased longevity of people with diabetes. Long-term consequences of DFU include decreased functional state of the patient with increased infection, hospitalisation and lower-extremity amputation. Pathologies such as loss of sensation, ischaemia and minor trauma are also well established in DFUs. Morbidity following DFU is high with recurrence rates of 65% in 3–5 years. Lifetime lower-extremity amputation incidence is 20%. New data suggest that lower extremity amputation incidence has increased by 50% in some regions

over the past several years. Efforts to improve patient care in allopathy with DFU have not resulted in consistently lower amputation rates.^[3] It makes it even more difficult in countries with large population like India to provide special attention and personalised care to the patient. This widening disparity in DFU patient care and amputation rates can be improved if different systems of medicine can provide a reliable mode of treatment in treating such topical cases. Homoeopathy has a lot to offer to society if practised with proper understanding and precision, as reported by recent studies/case series.^[4-6] It can even help in reducing hospitalisation and amputation rates with just outpatient department (OPD) care services. The following case report describes one such case of DFU with type 2 DM (ICD-10-CM Code: E11.621) treated with homoeopathic medicines and assessed with Outcomes Related to Impact on

***Address for correspondence:** Niharika Shaw,
National Institute of Homoeopathy, Kolkata, West Bengal, India.
E-mail: drniharikashaw@gmail.com

Received: 7 August 2023; **Accepted:** 18 June 2024

Access this article online

Quick Response Code:



Website:
www.ijrh.org

DOI:
10.53945/2320-7094.1931

This is an open access journal, and articles are distributed under the terms of the Creative Commons Attribution-NonCommercial-ShareAlike 4.0 License, which allows others to remix, tweak, and build upon the work non-commercially, as long as appropriate credit is given and the new creations are licensed under the identical terms.

How to cite this article: Singh L, Manoharan R, Shaw N, Ansari S. Diabetic foot ulcer treated with the homoeopathic medicine *Lachesis mutus* in millesimal potencies: A case report. Indian J Res Homoeopathy 2024;18:147-153.

Daily Living (ORIDL)^[7] and Modified Naranjo Criteria for Homoeopathy (MONARCH)^[8] scores.

PATIENT INFORMATION

A 52-year-old male, farmer by profession, presented in OPD of the National Institute of Homoeopathy, Kolkata, on August 16th, 2022 with the complaint of ulcer and swelling on the left great toe and over the medial malleolus of the right foot with an electric sensation-like pain radiating upwards in both legs. Ulcers were reported to be painless. The ulcer on the left great toe measured around 2 × 3 cm and the one over the right medial malleolus measured about 4 × 5 cm. These ulcers had irregular margins and sloping edges with the base containing a variable amount of slough, necrotic tissue, exudate and blackish discoloration of the skin around the ulcers. There was an offensive yellowish thick discharge from the ulcer [Figure 1]. The patient developed this wound over the left great toe after a mongoose's bite nine years ago, which never recovered fully, and aggravated in the past year. The patient said that the repeated wounds due to the painlessness nature of the ulcer, as well as improper care, led to this condition of his foot. He had used several ointments externally for treating the ulcer but in vain.

The patient was diagnosed with diabetes mellitus type-2, 15 years ago and reported himself as highly diabetic. However, he did not have any past medical records to confirm this, nor was he taking any medicine for the treatment of diabetes, thus leaving the condition uncontrolled. His blood sugar level was noted to be 147 mg/dL while fasting and 216 mg/dL in the post-prandial period. In the past, he had suffered from chicken pox, measles, typhoid fever and jaundice. No significant family medical history was reported by the patient. None of his parents or siblings suffered from diabetes type-2.

Clinical findings

On clinical examination, the ulcers were found to be non-tender with irregular margins and sloping edges. Painless ulcers were located over the medial malleolus of the right foot and

left great toe.

On general physical examination, the patient appeared anxious. He was of moderate stature and weighed 68 kg. His tongue was dry, trembling and got caught between his teeth while protruding tongue for long. His face was sufficiently flushed. No signs of anaemia, cyanosis or hyperbilirubinaemia could be traced. No arteries or veins were engorged, nor any lymph nodes were swollen.

Generals

The patient was irritable and anxious about his health condition. He used to get angry easily, though he desired to be consoled for all his complaints. He was bothered about no one taking care of his disease seriously or taking care of him. He was forgetful. He was also loquacious and could not bear any tight clothing on his body. He had some unusual fear of snakes also as mere imagination of snakes would give him goosebumps.

His appetite was more than usual, with intolerance to hunger. The patient had a strong desire for warm food and sour things. Thermally, the patient was hot but had a tendency to catch cold easily with profuse, offensive sweat. The sleep of the patient was sound but he had frequent dreams of snakes.

Diagnostic assessment

After clinical examination, the ulcers were found to be non-tender with irregular margins and sloping edges. The ulcer was pale and suppurative. Considering the non-healing nature of the ulcer following trauma in a known case of uncontrolled diabetes, the ulcers were diagnosed as DFUs with Type 2 DM (ICD-11-MMS Code: BD54).

Therapeutic intervention

The selection of the remedy was done based on repertorisation by RADAR software version 10.0^[9] using the Repertory of J.T. Kent. The repertorisation chart is shown in Figure 2. In the chart, *Lachesis mutus* scored 7/14 in the reportorial results covering 7 out of 9 rubrics that were considered for the analysis.

16 doses of *Lachesis mutus* 0/1 were prescribed, followed by 16 doses of *Lachesis mutus* 0/2. Six globules (Globule No. 20) of each potency were dispensed in 100 ml of distilled water. Ten drops of rectified spirit were added as a preservative. The patient was asked to take medicine every morning on an empty stomach after ten downwards succussions and report after one month.

The medicine was administered orally. The potency, dosage and repetition of the medicine were decided as per the principles of Homoeopathy. No external application was used. The cleaning of the wound was advised twice daily with normal saline. Dressing of the wound was done by the concerned on-duty PGT under the guidance of medical dresser of the hospital in inpatient department (IPD) of the hospital.

Follow-up and outcomes

The details of follow-ups are mentioned in Table 1.

Photograph-based evidence of improved ulcer on the left great toe and right middle malleolus is shown in Figure 3.

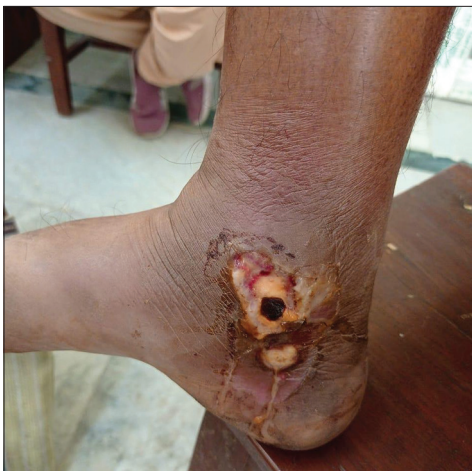

Figure 1: Diabetic foot ulcer before treatment (First visit - 16 August 2022)

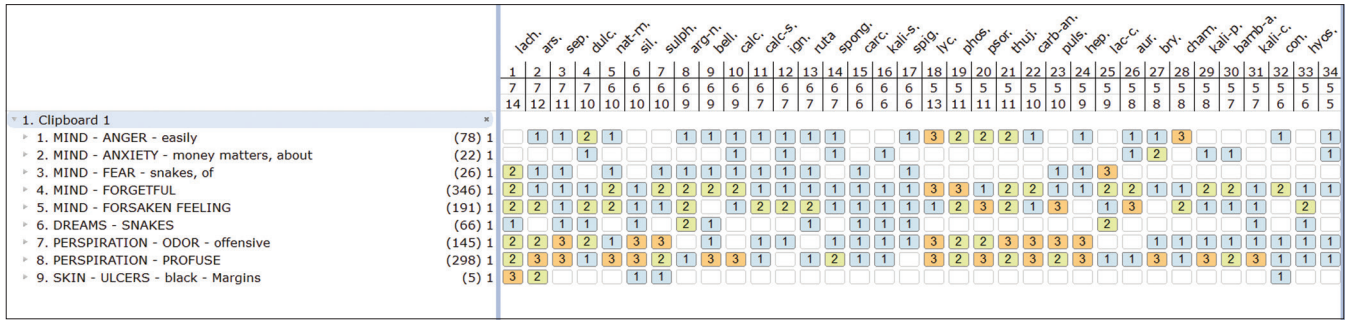


Figure 2: Repertorisation chart using RADAR software®

Date	Symptom	Medicine potency and doses	Justification	ORIDL	
				MC	OWB
First visit 16 August 2022	<ul style="list-style-type: none"> Easily angered. Anxiety. Dreams of snakes. Profuse, offensive perspiration. Ulcer on the left great toe and medial malleolus of the right foot. 	<p><i>Lachesis mutus</i> 0/1 16 Doses OD×16 days</p> <p><i>Lachesis mutus</i> 0/2 16 Doses OD×16 days</p> <p>Medicine to be taken every morning in empty stomach after 10 downwards succussions</p>	<ul style="list-style-type: none"> Based on the totality of symptoms followed by repertorisation. 		
21 September 2022	<ul style="list-style-type: none"> Marked improvement in the mental and physical sphere of the patient noted. Marked improvement was visible on the areas of ulcer over left great toe. Necrotic tissue debris on ulcers reduced. Blackish discharge reduced. Size of ulcer was measured as 2×2 cm. 	<p><i>Lachesis mutus</i> 0/3 16 Doses OD×16 days</p> <p>↓</p> <p><i>Lachesis mutus</i> 0/4 16 Doses OD×16 days</p> <p>Medicine to be taken every morning in empty stomach after 10 downwards succussions</p>	<ul style="list-style-type: none"> Improvement in the mental and physical symptoms were remarkable. Any kind of improvement in case debars from discontinuation or change of remedy. Therefore, same medicine was continued in the next LM potencies. 	-	-
13 October 2022	<ul style="list-style-type: none"> No necrotic tissues were seen. No discharge was seen. Size of the ulcer reduced to 1×1 cm. Ulcer margins improved with new granulation tissues at base of ulcer. 	<p><i>Lachesis mutus</i> 0/5 16 Doses OD×16 days</p> <p>↓</p> <p><i>Lachesis mutus</i> 0/6 16 Doses OD×16 days</p> <p>Medicine to be taken every morning in empty stomach after 10 downwards succussions</p>	<ul style="list-style-type: none"> Same medicine continued in the next potencies since slow and continuous improvement was seen on ulcers. 	+1	+1
10 November 2022	<ul style="list-style-type: none"> Ulcer was healed completely. Base of the ulcer filled with healthy tissues. Edges cleared up with regular margins. No altered pigmentation seen. 	<p><i>Lachesis mutus</i> 0/7 16 Doses OD×16 days</p> <p>↓</p> <p><i>Lachesis mutus</i> 0/8 16 Doses OD×16 days</p> <p>Medicine to be taken every morning in empty stomach after 10 downwards succussions</p>	<ul style="list-style-type: none"> Treatment continued for curing the case completely. 	+2	+2
Total score				+3	+3

In every visit, subsequent potencies were prescribed with 16 doses of each potency for 32 days. MC: Main complaints, ORIDL: Outcome Related to Impact on Daily Living, OWB: Overall well being

The patient's improvement was assessed using the ORIDL scale, widely used for the assessment of improvement in main complaints along with the overall well-being of the patient as per their subjective experience. The score gradually shifted to positive, with a final score of +3, which suggests a marked improvement [Table 1]. The MONARCH was applied to the case to see whether the clinical improvement in the case was due to the given intervention or not, and with a score of +8, we can attribute the recovery to the homoeopathic treatment [Table 2].

DISCUSSION

DFU cases are known to be treated successfully with the homoeopathic system of medicine, as also mentioned in the evidence-based literature on Homoeopathy. A study conducted by Nayak *et al* investigated the effectiveness of

15 pre-defined homoeopathic medicines such as *Silicea*, *Sulphur*, *Lycopodium*, *Arsenicum album* and *Phosphorous* in the treatment of chronic foot ulcers. It concluded that there was a significant improvement in the ulcer assessment score after the treatment. However, it also reported other supportive measures for ulcer management as possible confounders for the results.^[4]

Another study by Mahesh *et al* revealed that individualised homoeopathic medicine such as *Pulsatilla*, *Staphysagria*, *Lachesis*, *Lycopodium*, *Nux vomica* and *Aurum metallicum* can help in dealing with the most troublesome and challenging disease conditions, such as stasis dermatitis associated with chronic venous ulcers.^[5]

Further, a pilot study by Ponnam *et al* confirms that the individualised homoeopathic medicines, along with proper management of wounds irrespective of applying *Calendula* mother tincture or normal saline and standard conventional diabetic management, can effectively manage the Wagner's first and second stages of DFUs.^[6]

An individualised patient care is the need of the hour in medical science. In Homoeopathy, patients are considered as a whole and the similimum is selected based on the totality of symptoms, which includes the patient's mental, physical and characteristic particular symptoms. The symptoms under totality are repertorised and individualised homoeopathic medicine is selected after consulting Materia Medica literature, on the basis of which the remedy, *Lachesis mutus*, was differentiated from the other similar high-scoring remedies such as *Arsenicum album*, *Sepia*, *Dulcamara* and *Natrum muriaticum* obtained from the repertorial analysis.^[10] Strong physical generalities, like trembling of the tongue, which catch in between teeth, and pathological symptoms like painless ulcers around the ankles

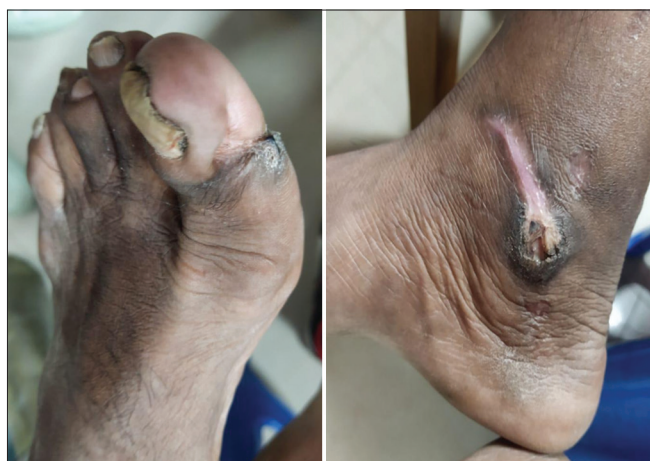

Figure 3: Diabetic foot ulcers after treatment (10 November 2022)

Table 2: Assessment by Modified Naranjo Criteria for Homoeopathy

Criteria	Yes	No	Not sure or N/A know
1. Was there an improvement in the main symptom or condition for which the homeopathic medicine was prescribed?	+2	-1	0
2. Did the clinical improvement occur within a plausible timeframe relative to the medicine intake?	+1	-2	0
3. Was there a homeopathic aggravation of symptoms?	+1	0	0
4. Did the effect encompass more than the main symptom or condition (i.e., were other symptoms, not related to the main presenting complaint, improved or changed)?	+1	0	0
5. Did overall well-being improve? (Suggest using a validated scale or mention about changes in physical, emotional and behavioural elements)	+1	0	0
6A. Direction of cure: did some symptoms improve in the opposite order of development of symptoms of the disease?	+1	0	0
6B. Direction of cure: did at least one of the following aspects apply to the order of improvement in symptoms: - from organs of more importance to those of less importance? - from deeper to more superficial aspects of the individual? - from the top downwards?	+1	0	0
7. Did "old symptoms" (defined as non-seasonal and non-cyclical symptoms that were previously thought to have resolved) reappear temporarily during the course of improvement?	+1	0	0
8. Are there alternate causes (i.e., other than the medicine) that – with a high probability – could have produced the improvement? (Consider the known course of the disease, other forms of treatment and other clinically relevant interventions)	-3	+1	0
9. Was the health improvement confirmed by any objective evidence? (e.g., investigations, clinical examination, etc.)	+2	0	0
10. Did repeat dosing, if conducted, create similar clinical improvement?	+1	0	0
Total score	+8		

* The numbers in the bold font represent the options selected

and toe with black margins, which developed after the bite of a mongoose and fear of snakes strongly suggested the case in favour of *Lachesis mutus*. His physical ailments, along with financial constraints in life, made him weak, both mentally and physically. All these traits together strongly suggested *Lachesis mutus* as the medicine of choice.

This case of DFU showed a good recovery with homoeopathic medication within a short span of three months. There was a noticeable improvement in the primary symptom of the case, as also documented in the photographs [Figures 1 and 3]. The ORIDL score of +3 suggested improvement in the patient's mental and physical generals, thus also indicating an overall improvement in the patient's well-being. This was achieved without using any kind of external ointment. The MONARCH for the case was +8, which suggested a definite association between the intervention and the outcome.

However, randomised, double-blind clinical trials need to be conducted to draw any strong conclusion about the efficacy of individualised homoeopathic medicine, without external application, in the treatment of DFUs.

CONCLUSION

This case of DFU showed promising results from internal medication. The homoeopathic treatment of DFUs can result in reduced hospitalisation, lesser cost of treatment and also bring down amputation rates of DFU patients, thus recommending more focus on further research of managing DFUs with Homoeopathy.

Declaration of patient consent

The author certifies that the patient had given his written informed, consent for using his clinical information and photographs in a non-revealing manner for reporting in a journal. The patient understands that due efforts will be made to conceal his identity, but anonymity cannot be guaranteed.

Financial support and sponsorship

Nil.

Conflict of interest

None declared.

REFERENCES

1. Maiti S, Akhtar S, Upadhyay AK, Mohanty SK. Socioeconomic inequality in awareness, treatment and control of diabetes among adults in India: Evidence from National Family Health Survey of India (NFHS), 2019-2021. *Sci Rep* 2023;13:2971.
2. McDermott K, Fang M, Boulton AJ, Selvin E, Hicks CW. Etiology, epidemiology, and disparities in the burden of diabetic foot ulcers. *Diabetes Care* 2023;46:209-21.
3. Moss SE, Klein R, Klein BE. The prevalence and incidence of lower extremity amputation in a diabetic population. *Arch Intern Med* 1992;152:610-6.
4. Nayak C, Singh V, Singh K, Singh H, Gupta J, Ali MS, *et al*. A prospective observational study to ascertain the role of homoeopathic therapy in the management of diabetic foot ulcers. *Indian J Res Homoeopathy* 2012;6:22.
5. Mahesh S, Mallappa M, Shah V, Vithoulkas G. Venous ulcer and stasis dermatitis treated with classical homoeopathy: A case series. *Indian J Res Homoeopathy* 2021;15:247-55.
6. Ponnampalani H, Lamba C, Oberai P, Masood S, Yandamuri S, Rao M, *et al*. *Calendula* mother tincture vs normal saline for ulcer dressing as an add-on to individualised homoeopathic intervention in the management of diabetic foot ulcer: A randomised controlled pilot study. *Indian J Res Homoeopathy* 2020;14:233-41.
7. Reilly D, Mercer SW, Bikker AP, Harrison T. Outcome related to impact on daily living: Preliminary validation of the ORIDL instrument. *BMC Health Serv Res* 2007;7:139.
8. Lamba CD, Gupta VK, Van Haselen R, Rutten L, Mahajan N, Molla AM, *et al*. Evaluation of the modified Naranjo Criteria for assessing causal attribution of clinical outcome to homeopathic intervention as presented in case reports. *Homeopathy* 2020;109:191-7.
9. Archibel. RADAR 10. Archibel Homoeopathic Software. Isnes, Belgium: Archibel; 2018. Available from: <http://www.archibel.com> [Last accessed on 2023 Apr 16].
10. Boericke W. Boericke's New Manual of Homoeopathic Materia Medica with Repertory. 9th ed. New Delhi: B. Jain Publishers Pvt Ltd; 2013.

Ulcère du pied diabétique traité avec le médicament homéopathique *Lachesis mutus* à des puissances millimésimales : un rapport de cas

Introduction: L'ulcère du pied diabétique (UPD) est la complication neuropathique la plus courante du diabète. Un diabète non contrôlé et des soins inadéquats des pieds entraînent des maladies graves comme l'UPD à la suite de blessures mineures. Un habillage régulier et des soins appropriés des pieds sont nécessaires pour son amélioration. Les patients n'ont d'autre choix que l'amputation du membre. S'habiller pendant une période plus longue ne semble pas pratique et faisable du côté du patient. DFU a également la gangrène humide comme l'une de ses principales complications. **Résumé de cas:** Ce rapport de cas présente le cas d'un patient diabétique se plaignant d'un ulcère du pied depuis neuf ans, à la suite de la morsure d'une mangouste. Sur la base de l'ensemble des symptômes, une médecine homéopathique individualisée *Lachesis mutus* a été prescrite. L'ulcère s'est amélioré en trois mois après la médication homéopathique sans l'utilisation d'aucune application externe. L'amélioration a été illustrée dans le présent rapport de cas par des preuves pictographiques. L'évaluation subjective du cas a été effectuée à l'aide des critères de jugement liés à l'impact sur la vie quotidienne (ORIDL) et des critères modifiés de Naranjo pour l'homéopathie (MONARCH) pour évaluer la relation causal-effet dans le cas, qui a montré un score de +3 et +8, respectivement. L'amélioration de l'ulcère a également été évaluée par des photographies.

Diabetisches Fußgeschwür mit dem homöopathischen Arzneimittel *Lachesis mutus* in millesimalen Potenzen behandelt: Ein Fallbericht

Einleitung: Das diabetische Fußgeschwür (DFU) ist die häufigste neuropathische Komplikation von Diabetes. Unkontrollierter Diabetes und unsachgemäße Fußpflege führen zu schweren Erkrankungen wie DFU durch leichte Verletzungen. Regelmäßiges Anziehen und die richtige Fußpflege sind erforderlich, um es zu verbessern. Den Patienten bleibt keine andere Wahl als die Amputation der Extremität. Ein längeres Anziehen scheint für den Patienten nicht bequem und machbar zu sein. DFU hat auch feuchte Gangrän als eine seiner Hauptkomplikationen. **Fallzusammenfassung:** Dieser Fallbericht stellt einen Fall eines Diabetikers vor, der in den letzten neun Jahren nach dem Biss eines Mungos über ein Fußgeschwür klagte. Auf der Grundlage der Gesamtheit der Symptome wurde das individualisierte homöopathische Arzneimittel *Lachesis mutus* verschrieben. Das Geschwür besserte sich innerhalb von drei Monaten nach homöopathischer Medikation ohne äußere Anwendung. Die Verbesserung wurde in diesem Fallbericht durch bildliche Beweise dargestellt. Die subjektive Bewertung des Falles erfolgte unter Verwendung von Outcomes Related to Impact on Daily Living (ORIDL) und Modified Naranjo Criteria for Homeopathy (MONARCH) wurde verwendet, um die kausale Wirkungsbeziehung in dem Fall zu bewerten, die eine Punktzahl von +3 bzw. +8 aufwies. Die Verbesserung des Geschwürs wurde auch anhand von Fotos beurteilt.

मधुमेह के पैर के अल्सर का इलाज होम्योपैथी दवा लैकेसिस म्यूटस की मिलीसिमल पोटेंसी के द्वारा: एक केस रिपोर्ट

परिचय: मधुमेह संबंधी पैर का अल्सर (DFU) मधुमेह की सबसे आम तंत्रिका-सम्बन्धी जटिलता है। अनियंत्रित मधुमेह और पैरों की अनुचित देखभाल से मामूली चोटों से DFU जैसी गंभीर स्थिति पैदा हो जाती है। इसमें सुधार के लिए नियमित ड्रेसिंग और पैरों की उचित देखभाल की आवश्यकता होती है। नहीं तो मरीजों के पास अंग काटने के अलावा कोई दूसरा विकल्प नहीं बचता। लंबे समय तक ड्रेसिंग करना रोगी के लिए असुविधाजनक होता है। DFU की प्रमुख जटिलताओं में से एक गीला गैंग्रीन भी है। **केस सारांश:** यह केस रिपोर्ट एक मधुमेह रोगी का मामला प्रस्तुत करती है जो एक नेवले के काटने के बाद पिछले नौ वर्षों से पैर के अल्सर की शिकायत कर रहा था। लक्षणों की समग्रता के आधार पर, व्यक्तिगत होम्योपैथी दवा लैकेसिस म्यूटस विहित की गई, जिसके बाद तीन महीने में अल्सर में सुधार हुआ। इस केस रिपोर्ट में चित्रात्मक साक्ष्य के माध्यम से सुधार को दर्शाया गया है। मामले का व्यक्तिपरक मूल्यांकन दैनिक जीवन पर प्रभाव (ORIDL) द्वारा किया गया और मामले में कारण-प्रभाव संबंध का मूल्यांकन पाया गया मोनार्क के लिए संशोधित नारंजो मानदंड द्वारा किया गया, जिसमें +3 और +8 का स्कोर पाया गया। तस्वीरों के जरिए भी अल्सर में सुधार का आकलन किया गया।

Úlcera del pie diabético tratada con el medicamento homeopático *Lachesis mutus* en potencias milésimas: A reporte de un caso

Introducción: La úlcera del pie diabético (UPD) es la complicación neuropática más frecuente de la diabetes. La diabetes no controlada y el cuidado inadecuado de los pies conducen a afecciones graves como la DFU por lesiones menores. Para su mejoría es necesario un vendaje regular y un cuidado adecuado de los pies. A los pacientes no les queda otra opción que la amputación de la extremidad. Vestirse durante un período más largo no parece conveniente ni factible al final del paciente. La DFU también tiene gangrena húmeda como una de sus principales complicaciones. **Resumen del caso:** Este informe de caso presenta el caso de un paciente diabético que se queja de una úlcera en el pie durante los últimos nueve años, después de la mordedura de una mangosta. Sobre la base de la totalidad de los síntomas, se prescribió la medicina homeopática individualizada *Lachesis mutus*. La úlcera mejoró en tres meses después de la medicación homeopática sin el uso de ninguna aplicación externa. La mejora se ha descrito en este informe de caso a través de pruebas pictográficas. La evaluación subjetiva del caso se realizó utilizando los Resultados Relacionados con el Impacto en la Vida Diaria (ORIDL) y los Criterios Naranjo Modificados para la Homeopatía

(MONARCH) para evaluar la relación causal-efecto en el caso, los cuales mostraron una puntuación de +3 y +8, respectivamente. También se evaluó la mejoría de la úlcera a través de fotografías.

用顺势疗法药物 *Lachesis mutus* 治疗的糖尿病足溃疡在千禧年效力：病例报告

简介：糖尿病足溃疡（DFU）是糖尿病最常见的神经性并发症。不受控制的糖尿病和不当的足部护理会导致轻伤导致DFU等严重疾病。需要定期穿衣和适当的足部护理才能改善。患者别无选择，只能截肢。在患者末端，长时间的穿衣似乎既不方便也不可行。DFU还将湿性坏疽作为其主要并发症之一。**病例摘要：**本病例报告介绍了一名糖尿病患者在过去九年中被猫鼬咬伤后主诉足溃疡的病例。根据症状的整体情况，开具了个性化的顺势疗法药物 *Lachesis mutus*。顺势疗法药物治疗后三个月溃疡有所改善，无需使用任何外部应用。本病例报告通过象形证据描述了这种改善。使用与日常生活影响相关的结果（ORIDL）对病例进行主观评估，并使用改良的 Naranjo 顺势疗法标准（MONARCH）来评估病例的因果关系，得分分别为 +3 和 +8。溃疡的改善也通过照片进行了评估。