

## CLINICAL PAPER

# A case of haemorrhoids in a 12-year-old boy

Padmalaya Rath, Harleen Kaur<sup>1</sup>

### ABSTRACT

Haemorrhoids is a very common condition that a physician would encounter in day to day practice. However, haemorrhoids in children is not as common. The only known treatment for the condition in conventional medicine is surgical excision, which is generally not favoured at this age. The case reported here is that of an internal haemorrhoids in a 12-year-old child, who was treated successfully with homoeopathic medicine. The patient has been observed for more than 2 years without recurrence. Photographs were taken before and after treatment to record changes in the condition. Non-recurrence of complaint in the past two and half years suggests that a 'near permanent' cure is achievable through individualised homoeopathic treatment.

**Keywords:** Haemorrhoids, Dentate line, Individualized homoeopathy, Polyps, Phosphorus

#### Access this article online

**Website:**

[www.ijrh.org](http://www.ijrh.org)

**DOI:**

10.4103/0974-7168.129677

**Quick Response Code:**



Research Officer, Central Research Institute for Homoeopathy, <sup>1</sup>Senior Research Fellow, Central Research Institute for Homoeopathy, Noida, Uttar Pradesh, India

**Address for correspondence:**

Dr. Padmalaya Rath,  
A 1/1, Sector 24, Noida, India.  
E-mail: [drpadmalaya@gmail.com](mailto:drpadmalaya@gmail.com)

**Received:** 05-08-2013

**Accepted:** 17-02-2014

### INTRODUCTION

Haemorrhoids are enlarged veins located in the lower part of the rectum and the anus. External haemorrhoids originate below the dentate line, while internal haemorrhoids are above the line and are classified according to their degree of prolapse from the anal canal.<sup>[1]</sup> Haemorrhoids Grade I - are visualised on anoscopy, bulge into the lumen but do not extend below the dentate line, Grade II- prolapse out of the anal canal with defecation or with straining but reduce spontaneously, Grade III - prolapse out of the anal canal with defecation or straining, and require reduction, Grade IV haemorrhoids - are irreducible and may strangulate.<sup>[2,3]</sup> It is important to differentiate a haemorrhoids from other growths like anal papillae or polyps. Polyps are usually asymptomatic but occasionally grow large enough to be felt by the patient or are likely to prolapse.

Hypertrophied anal papilla, composed of a smooth mass located near the anal verge, is also considered a differential diagnosis especially in a patient with a history of chronic anal irritation or infection.<sup>[4]</sup>

About 75% of people will have haemorrhoids at some point in their lives.<sup>[5]</sup> Haemorrhoids is most common among adults aged 45-65.<sup>[6]</sup> About 80% of people in India develop haemorrhoids. and about 80% aged over 50 have some form of symptomatic haemorrhoidal disease.<sup>[7]</sup>

However, haemorrhoids in children are not as common.<sup>[8,9]</sup> Some common symptoms include bleeding from the rectum, anal itching, general discomfort and an external anal protrusion. Children who are suffering from this condition should be treated quickly and monitored carefully in order to prevent the development of infections associated with the condition. Typically, when treated quickly

and properly, haemorrhoids cause no lasting effects on the children.<sup>[10]</sup> In this case report we describe one such patient.

## CASE REPORT

A 12-year-old boy presented with bleeding from anus since 3 years. Patient complained of some projection from anus, accompanied with bleeding during passage of stool. The patient reported of pushing up the protrusion by hand after defaecation. There was no history of pain. The patient did not take any prior treatment before reporting for homoeopathic medication. He had been advised surgery and the usual fear of surgery prompted his parents to seek homoeopathic treatment. Subsequently, the patient was brought to the OPD of CRI (H), Noida. On physical examination, position of haemorrhoids was found to be 11'O clock [Figure 1].

The patient was non-vegetarian and of tall, lean built. His parents reported of his irritable nature and marked anxiety before examination at school. The patient was also observed to be anxious in general, a fact that was verified by his parents. His appetite was good and he desired both sweet and salty food items. He would also drink water frequently, about two glasses of water at a time. The boy was hot thermally, but also had a tendency to catch cold easily.

Family history: Mother - heavy menstrual flow

The following symptoms were considered for repertorisation:

- Anxiety
- Hot patient
- Tendency to catch cold
- Desire for sweet and salted things

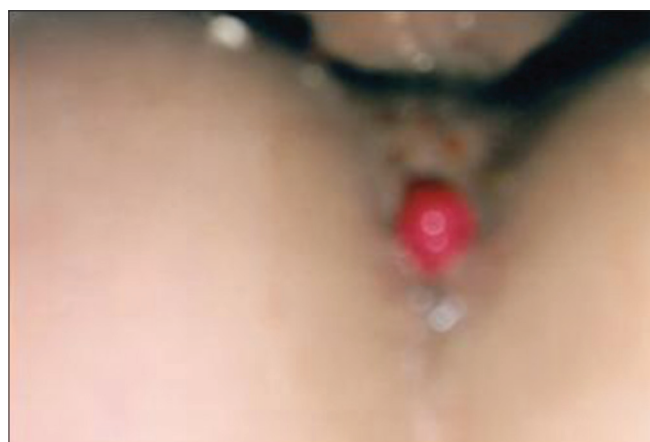


Figure 1: Internal hemorrhoid (Grade III) as observed on first visit (31.12.09)

- Thirst for large quantity
- Haemorrhoids protruding
- Haemorrhoids protruding, stool during
- Haemorrhoids bleeding.

The repertorial result that followed using Homopath Repertory (Classic M.D.) is shown in Table 1.

A detailed account of the treatment is given below.

### First Prescription (31.12.09)

*Phosphorus* 200/2 doses-OD \*2 days

Placebo 30/BD \*15 days

Advice: Sitz bath; restrict spicy and oily food.

### Basis of Prescription

In terms of repertorial scoring, both *Phosphorus* and *Sulphur* scored 23/10 and *Calcarea carb.* scored 21/9. In this case, *Phosphorus* was preferred as it is a known anti-haemorrhagic medicine. It is prescribed for discharge of blood from rectum during stool, bleeding haemorrhoids<sup>[11]</sup> and also known to cover the symptom 'painless stool' well. Further, to confirm the prescription of *Phosphorus* over other drugs, a detailed cross-reference study was done. It was found that the rubric, 'Haemorrhoids protrude stool during' is an important one but not covered by *Sulphur* in Kent and Synthesis repertories and is covered only in 1 grade in Complete repertory. Another rubric, 'Haemorrhage from anus stool during' has three marks in *Phosphorus* and only one mark in *Sulphur* as per Synthesis repertory, while the same doesn't find a mention in any other repertory that was consulted. *Calcarea carb.* on the other hand, though scored 21/9 and two marks in 'haemorrhoids protrude during stool', the patient's physical appearance was not in consonance with the drug.

The follow up is mentioned in detail in Table 2.

## RESULT

After prescription of *Phosphorus* in various potencies, the bleeding from haemorrhoids eventually stopped. However, there were a few intermittent episodes of bleeding before final cessation. Even the size of the protrusion reduced [Figure 2]. Later, in the due course of treatment, the haemorrhoids disappeared, as observed on 23<sup>rd</sup> March 2011 and confirmed by surgeon on 27<sup>th</sup> July 2011 [Figure 3]. Even after two years of stopping treatment, the patient has not reported of any recurrence.

Rath and Kaur:A cured case of haemorrhoids in a 12-year old boy

**Table 1: Hompath repertory (classic M.D.)**

**Repertorisation**  
Repertorisation: Symptoms Covered

2
 4
 4
 0
 0
 0

Remedy Name	Phos	Sulph	Calc	Merc	Nat-m	Nit-ac	Lyc	Ars	Caab-y	Chin	Bar-c	Kali-c
Totality	23	23	21	16	21	21	20	18	16	16	15	15
Symptom Covered	10	10	9	9	8	8	8	8	8	8	8	8
[C] [Mind]Anxiety:	3	3	3	2	2	3	3	3	3	3	2	3
[C] [Mind]Excitement, excitable:Tendency:	3	2	2	2	3	3	2	2	1	2	1	1
[C] [Generalities]Heat:Sensation of:	2	3	2	2	3	2	3	1	1	1	2	1
[C] [Generalities]Cold:Tendency to take, taking cold agg.:	2	2	3	3	3	3	3	2	2	1	3	3
[C] [Generalities]Food and drinks:Sweets:Desires:	2	3	2	2	1	2	3	3	2	3	1	2
[C] [Generalities]Food and drinks:Salt or salty food:Desires:	3	1	2	1	3	3			3	2		
[C] [Stomach]Thirst:Large quantities, for:	3	3			3			3		2		
[C] [Rectum]Hemorrhoids:Protruding, prolapsed:	1	2	2	1			1		2		1	1
[C] [Rectum]Hemorrhoids:Stool:Protrude:During:	1	1	2	1		2	2	1			2	2
[C] [Rectum]Hemorrhage:Anus, from:	3	3	3	2	3	3	3	3	2	2	3	2

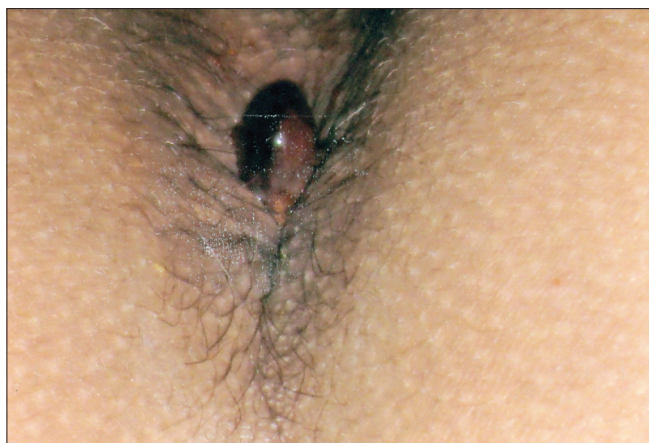
Symptoms **10**
Remedies **590**

**Table 2: Follow ups**

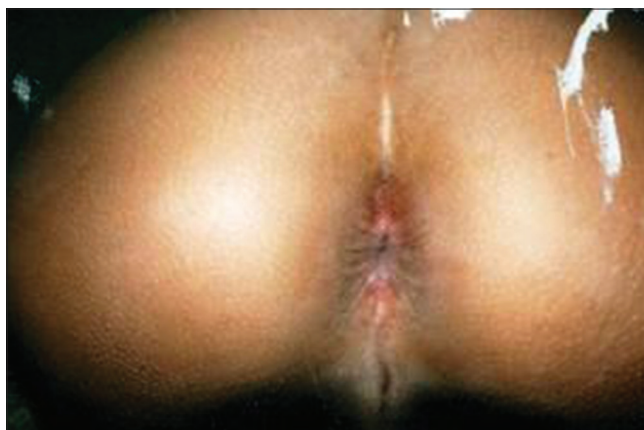Date	Symptoms	Medicine	Potency	Repetition	Days
01.02.10	Bleeding during stool-sometimes	<i>Phos.</i>	200	O.D.	2
	Size of protrusion during stool-no change	Placebo	30	B.D.	15
15.02.10	No bleeding during stool	Placebo	30	B.D.*	10
	Protrusion of mass: same as before				
08.03.10	Bleeding during stool: At times	<i>Phos.</i>	1M	O.D.	2
	Size of protruding mass: same as before	Placebo	30	B.D.	30
29.03.10	No bleeding during stool	Placebo	30	B.D.	15
	Size of protruding mass: same as before				
28.06.10	No bleeding during stool	<i>Phos.</i>	1M	O.D.	2
	Size of protruding mass: same as before	Placebo	30	B.D.	30
18.10.10	No bleeding during stool	Aloe socotrina	30	T.D.S.	3
	Size of protruding mass: same as before				
	Diarrhoea mucoid<morning (5-6 times in morning) since 2 days				
24.01.11	Heavy bleeding during stool in the morning	<i>Phos.</i>	1M	O.D.	2
		Advice: Sitz bath	30	B.D.	7
		Placebo			
02.02.11	No bleeding during stool	Placebo	30	B.D.	30
	Size of protruding mass: Reduced; No need to push the mass inside after stool; it goes in automatically (Figure 2)				
23.03.11	No bleeding during stool	<i>Sulphur</i>	1M	O.D.	2
	No protrusion of mass during passage of stool (Figure 3)	Placebo	30	B.D.	20
	No other complaints				
27.07.11	Proctoscopy done by surgeon reported no demonstrable pathology				
27.05.13	No demonstrable pathology still				

Phos: Phosphorus; O.D.: Once Daily; B.D.: Twice Daily; T.D.S: Thrice Daily





**Figure 2:** Non-bleeding haemorrhoids (02.02.11)



**Figure 3:** No protrusion/bleeding (23.03.11)

## DISCUSSION

Haemorrhoids in children, however uncommon, can result from unknown causes.

The disease, once established, tends to get worse over time. Medical application of creams and suppositories can relieve irritation and pain but rarely provide long-term benefit. A high fibre diet and bulk laxatives prevent constipation and worsening of the disease without achieving a cure. The mainstay of treatment is surgical. But unfortunately, operative haemorrhoidectomy is usually associated with significant postoperative complications, including pain, bleeding and anal strictures, which can result in protracted period of convalescence. Since surgery does not target the root causes like individual tendencies, habitual constipation, etc., recurrence is also common. Homeopathic medicines can modify these tendencies, thus reducing chances of recurrence significantly. Homeopathic literature mentions many medicines for the condition of which a similimum can help a patient for keeping the disease at bay for a longer period as evidenced in this case. Homeopathic remedies can offer gentle and safe relief. Patients have the highest satisfaction after taking the treatment. Mental makeup, physical makeup, sensations experienced by the patient, characteristics of haemorrhoids (bleeding, protruding, painful/painless), etc., also become a good tool for prescription. Besides, in a study on 78 patients between age group 25-60 years, homeopathic medicines in LM potencies was found to be effective ( $P=0.0001$ ) in treatment of internal haemorrhoids. This invites for further studies for evaluating the efficacy of the medicines in LM potencies in treating the condition.<sup>[14]</sup>

In this case, there was no history of repeated diarrhoea or intestinal infections that could have precipitated the development of haemorrhoids. Since there is no known precipitant for the condition, we may conclude that the difficulty was constitutional in origin and hence speaks of disordered susceptibility. A combination of lifestyle changes and homeopathic treatment proved to be a great relief to this patient and also eliminated the need for surgery. A thorough homeopathic treatment could remove the tendency and thereby prevent recurrence. Thus, the case also verifies the superiority of Materia Medica over repertory for correct choice of similimum. Phosphorus ultimately proved to be the correct choice as the first prescription, going by the result of the case. The dose 200 was selected in the beginning considering the severity of the case and the age of the child. However, it was increased to 1M when the bleeding recurred after stoppage even after two doses in 200 potency, which were allowed sufficient time to act. 1M potency was given with the hope that it would take the course of treatment further. Also, the size of mass did not reduce with the 200 potency. 1M was again repeated in due course, which finally also led to reduction and then final disappearance of the haemorrhoids. During the course of treatment, the patient once reported with diarrhoea, for which Aloe was given as an acute remedy. Sulphur was later given as an anti-psoric medicine to clear up the case at the conclusion. Proctoscopic examination by surgeon did not reveal any haemorrhoids or growth after treatment.

Although the case was successfully treated, a better compliance from the patient's side in terms of regular follow ups could have helped in quick

## Rath and Kaur: A cured case of haemorrhoids in a 12-year old boy

recovery of patient. The patient was requested to show up regularly, but owing to the improvement in condition, the patient preferred to report only when his parents felt that the medication was needed. This led to long gaps in medication periods, but it did not seem to affect the case adversely.

### CONCLUSION

Homoeopathy can take care of chronic problems in an individual, where surgery is otherwise advised. Non-recurrence of complaint in past two and half years suggests that haemorrhoids can be treated successfully through individualised homoeopathic treatment. However, the results from this single case report are by no means conclusive regarding the long-term clinical effectiveness of homeopathy for haemorrhoids in children. Well designed studies are required for establishing effectiveness and efficacy of homoeopathy in treating the condition.

### REFERENCES

1. Parker GS. A new treatment option for grades III and IV hemorrhoids Supplement to. J Fam Pract 2004;800.
2. Banov L Jr, Knoepf LF Jr, Erdman LH, Alia RT. Management of haemorrhoidal disease. J S C Med Assoc 1985;81:398-401.
3. Parker GS, Mindy E. W Procedure for Prolapse and Hemorrhoids:

- A New Approach to a Gynecologic Dilemma; Supplement to OBG management; August 2005; S3-7.
4. Gupta PJ. Hypertrophied anal papillae and fibrous anal polyps, should they be removed during anal fissure surgery? World J Gastroenterol 2004;10:2412-4.
5. Baker H. Hemorrhoids. In: Longe JL, editor. Gale Encyclopedia of Medicine. 3rd ed. Detroit: Gale; 2006. p. 1766-9.
6. Chong PS, Bartolo DC. Hemorrhoids and fissure in ano. Gastroenterol Clin of North Am 2008;37:627-44, ix.
7. Treatment for hemorrhoids; the hindu; August 15, 2010. Available from:<http://www.thehindu.com/todays-paper/tp-features/tp-downtown/treatment-for-hemorrhoids/article571441.ece>[Last accessed on 2013 May 27].
8. Heaton ND, Davenport M, Howard ER. Symptomatic hemorrhoids and anorectal varices in children with portal hypertension. J Pediatr Surg 1992;27:833-5.
9. Bartosh AM, Siubryts'ky MM. Combined hemorrhoids in early childhood. Klin Khir 1998;49-50. Available from:<http://www.wisegEEK.com/what-are-the-symptoms-of-hemorrhoids-in-children.htm> [Last accessed on 2013 May 27].
10. Available from:<http://www.wisegEEK.com/what-are-the-symptoms-of-hemorrhoids-in-children.htm> [Last accessed on 2013 May 27].
11. Willam B. Pocket manual of homoeopathic materia medica and repertory, Reprint ed. New Delhi: B Jain Publisher; 2007. p. 507-11.
12. Agbo SP. Surgical management of hemorrhoids. J Surg Tech Case Rep 2011;3:68-75.
13. Karnalkar N. Hemorrhoids: Hygeia. J Drugs Med 2012;4:2.
14. Chakraborty PS, Varanasi R, Majumdar AK, Banoth K, Prasad S, Ghosh MS, *et al*. Effect of homoeopathic LM potencies in acute attacks of haemorrhoidal disease: A multicentric randomized single-blind placebo-controlled trial. Indian J Res Homoeopathy 2013;7:72-80.

**How to cite this article:** Rath P, Kaur H. A case of haemorrhoids in a 12-year-old boy. Indian J Res Homoeopathy 2014;8:37-41.

**Source of Support:** Nil, **Conflict of Interest:** None declared.

### EDITOR'S NOTE

While the results of Homoeopathic intervention are miraculous, explanations for the choice of the remedy are often complex and controversial. Also there are several alternative methods of posology and the timing for the introduction of homoeopathic remedies, the rules of which have not yet been clearly

enunciated. For instance, when do we conclude that a particular patient is hot? What sort of data would justify such a conclusion? And which rubrics would accurately represent this thermal status? When do we conclude that the action of a remedy is over and the patient needs a complementary follow up remedy?. These aspects need to be researched to evolve a standardized homoeopathic treatment regime.

**पृष्ठभूमि:** हीमोराइड एक बहुत ही सामान्य स्थिति है जिसका चिकित्सक दिन प्रतिदिन इलाज के दौरान सामना करते हैं। हालांकि हीमोराइड बच्चों में सामान्य नहीं है, यहाँ जो मामला प्रतिवेदित किया है वो 12 साल के बच्चे में आन्तरिक हीमोरोइड का है जोकि होम्योपैथिक औषधि के द्वारा सफलतापूर्वक उपचारित किया गया। रोगी को 2 साल से ज्यादा दिन आवर्तन के द्वारा निरीक्षण किया गया। इस स्थिति के लिये केवल एक ही पारम्परिक उपचार शल्यचिकित्सा ज्ञात है। जोकि इस उम्र में अच्छा नहीं है। हीमोराइड से पीड़ित बारह साल के बच्चे को व्यक्तिगत होम्योपैथिक उपचार दिया गया। इलाज के पहले व बाद की स्थिति में हुए परिवर्तन को दर्ज करने के लिये उसकी फोटो ली गयी।

**परिणाम:** इस बच्चे में तीन वर्ष से हो रही हीमोराइड का होम्योपैथी द्वारा सफलतापूर्वक उपचार किया गया एवं इसकी ढाई साल में इसकी पुनरावृत्ति नहीं हुई।

**निष्कर्ष:** जहाँ शल्य चिकित्सा की सलाह दी जाती है, वहाँ होम्योपैथी व्यक्तिगत रूप से कुछ पुरानी बीमारियों का इलाज कर सकती है। ढाई साल में बीमारी की पुनरावृत्ति न होना यह सुझाता है कि व्यक्तिगत होम्योपैथिक उपचार से लगभग स्थायी इलाज किया जा सकता है।