

# Individualized homoeopathic treatment of breast fibroadenoma: A case report

Suraia Parveen\*

Research Officer (Homoeopathy)\*, Dr. Anjali Chatterjee Regional Research Institute (H), Kolkata, West Bengal, India

## Abstract

Fibroadenoma is the commonest benign breast tumor in adolescent and young women. Conservative management with regular observation is the rule for newly diagnosed patients. For progressive growth in young patients or failure of regression in patients above 35 years surgical intervention is contemplated. But there may be recurrence after surgery and patients are often apprehensive of surgery. Here, a 18-year-old girl presented with a palpable, non-tender, movable lump in the left breast at upper outer quadrant progressively increasing in size over last 2 years and was advised for surgery. Sonomammography and FNAC confirmed it as simple fibroadenoma (3.48 × 2.38 centimeter). She was successfully treated by individualized homoeopathic treatment with single medicine *Pulsatilla nigricans* over 15 months. Serial Sonomammography reports revealed progressive regression of Fibroadenoma to non palpable state. Possible causal attribution of changes was explicitly depicted by Naranjo Criteria. It shows positive role of Homoeopathic treatment in regression of fibroadenoma in a young woman.

**Keywords:** Fibroadenoma-Breast, Homoeopathy, Naranjo criteria, *Pulsatilla nigricans*, Single-medicine

## INTRODUCTION

Fibroadenoma (FA) is a benign breast lesion, usually found in adolescent and young women but may be discovered at any age. FA is assumed to be aberrations of normal breast development or the product of hyperplastic processes, rather than true neoplasm. FAs are usually smooth, clearly demarcated, firm, mobile, nontender, and rubbery in consistency. Usually, they exist as unilateral, solitary mass; however, in 10%–25% of cases, there may be multiple masses and occur bilaterally. FA can be located anywhere in the breast, but the majority are situated in the upper outer quadrant. Their size may vary from 1 to 10 cm, but mostly 2–3 cm.<sup>[1,2]</sup> There may be subcategories of FAs including simple FA, giant juvenile FA, and multicenter FA. The most common type (70%–90%) of FA is simple solitary FA; however, in multicenter FAs, they appear as multiple masses in different quadrant. Giant juvenile FAs are defined as any rapidly enlarging encapsulated FA with a diameter >5 cm. They may also be associated with skin changes and venous engorgement. The multicenter, bilateral FA (complex FA) may have familial preponderance.<sup>[3]</sup>

Simple FAs are most often detected incidentally during a medical examination or during self-examination. They are

more frequent among young women with obesity, in higher socioeconomic classes and dark-skinned populations. The age of menarche and any hormonal therapy including oral contraceptives do not alter the risk of these lesions. No genetic factors are found to alter the risk of simple FA.<sup>[4]</sup>

Several other breast lesions may have similar clinicopathological characteristics of FA. Studies showed that physical examinations failed to provide an accurate diagnosis in one-third to one-half of cases. Thus, sonomammography and fine-needle aspiration cytology (FNAC) are required in distinguishing FAs from other breast masses including breast cancer. There are some overlaps in the sonographic criteria for FAs and breast cancer as both of them are solid masses. Approximately 25% of FAs appear with irregular margins, which may raise the suspicion of malignancy. The yield of X-ray mammography in young women is low, and its role in the diagnosis of FA is limited as there is no calcification. Thus, FNAC is essential for confirmatory diagnosis of FA.<sup>[5]</sup>

**\*Address for correspondence:** Dr. Suraia Parveen,

Dr. Anjali Chatterjee Regional Research Institute (H), 50, Rajendra Chatterjee Road, Kolkata - 700 035, West Bengal, India.  
E-mail: [drsuraia@gmail.com](mailto:drsuraia@gmail.com)

### Access this article online

#### Quick Response Code:



Website:  
[www.ijrh.org](http://www.ijrh.org)

DOI:  
10.4103/ijrh.ijrh\_1\_16

This is an open access journal, and articles are distributed under the terms of the Creative Commons Attribution-NonCommercial-ShareAlike 4.0 License, which allows others to remix, tweak, and build upon the work non-commercially, as long as appropriate credit is given and the new creations are licensed under the identical terms.

**For reprints contact:** [reprints@medknow.com](mailto:reprints@medknow.com)

**How to cite this article:** Parveen S. Individualized homoeopathic treatment of breast fibroadenoma: A case report. Indian J Res Homoeopathy 2018;12:46-52.

The natural history of FA varies from individual to individual. Some FAs may remain dormant without any change in size. In most of the patients, there may be slowly waxing and waning of sizes without associated pain or skin changes. Usually, FAs show spontaneous regression in 10%–40% of population during observation. The risk of transformation from FA to cancer is rare unless the tumor or the surrounding breast parenchyma shows proliferative changes in serial investigation or the patient has a family history of breast cancer. However, this risk rises above the age of 35 years. Regular follow-up with sonomammographic evaluation at least every 6 months interval is the rule until there is complete regression. Apart from risk of carcinoma, increase in size or failure of regression of FA during observation causes psychological distress with discomfort and esthetic distortion. Usually, other than regular observation, there is no role for allopathic medication under conservative treatment. Surgical excision is considered for patients <35 years when there is progressive increase in size of the mass or failure of regression in patients above 35 years of age. Surgical excision under local anesthesia is done in those cases. However, in spite of successful percutaneous excision, FAs have been reported to recur. In young unmarried females, postoperative scar mark in the breast is a matter of great concern to many of them. Thus, definitive treatment with sustained recovery is still elusive for FA.<sup>[6,7]</sup>

Literature review on use of homoeopathic treatment on FA had revealed a double-blinded randomized trial of *Phytolacca* showing decrease in size in 69% of FAs in the experimental group whereas only 36% did so in the placebo group.<sup>[8]</sup> In another study on 135 patients of various benign breast lesions, constitutional homoeopathic treatment showed positive response in 73 (54.08%) patients. Out of them, complete resolution of lesions in 24 (17.78%) and significant reduction in 49 patients (36.30%). Thirty patients (22.22%) maintained status quo and 32 patients (23.70%) did not improve. Out of the total 135 patients, 98 (72.59%) were of FA. The period of treatment varied from case to case depending on size, type, and number of breast lesions.<sup>[9]</sup>

## PATIENT INFORMATION

An 18-year-old Hindu unmarried college girl from lower socioeconomic status family presented at Dr. Anjali Chatterjee Regional Research Institute for Homoeopathy (DACRRIH), Kolkata, in August 2014 with a progressively increasing palpable painless lump in her left breast since 2 years.

She had nil contributory ongoing medical present and past history. Her menstrual cycle was regular (28–30 days), moderate flow, and lasting for 2–3 days. There was history of severe pain in the first 2 days of menstruation (dysmenorrhea), ameliorating on rest. There were no other associated symptoms and no history of intake of oral contraceptive pill.

Her childhood history was uneventful. She was pursuing graduation studies. Her father was a security guard of lower-middle socioeconomic status. In her family, there was

a history of FA of the right breast in her paternal aunt who was operated for the lump but had recurrence. Subsequently, she was maintained on Homoeopathy for more than 5 years, details of which are not known. In others, paternal grandfather had diabetes and maternal grandmother was hypertensive. However, there was no history of malignancy.

Before coming to DACRRIH, Kolkata, she was under observation of a surgeon, evaluated by sonomammography, and waited for spontaneous resolution for 1 year. However, rather than regression, there was increase in size during observation. The lesion became 2.9 cm × 2.1 cm (sonomammography) on June 23, 2014, causing discomfort and psychological distress to the client. At this point, she was advised to undergo resection of the lump by surgeon. However, she was apprehensive of surgery for scarring of the breast and chances of recurrence. Thus, she decided for taking homoeopathic treatment as alternative method and came to DACRRIH outpatient department.

## CLINICAL FINDINGS

On clinical examination, it was revealed a nontender, mobile, firm, smooth, well-circumscribed mass with smooth margin in the upper and outer quadrant of the left breast. There was no asymmetry of both breast, no changes in skin, areola, and nipple, with no history of nipple discharges. The lump was movable with no adherence with skin and internal structure. There were no palpable axillary and clavicular lymph nodes. The patient had height 148 cm, weight 38 kg, body mass index 17.35, and fair complexion.

Along with this chief complaint, there were also complaints of unexplained anxiety, especially in crowd and public places with intermittent fear of death. There was painful menstruation (dysmenorrhea), vertigo with nausea/vomiting during car riding (motion sickness), and recurrent throbbing headache worse after exposure to the sun or exertion and relief from rest.

## Other homoeopathic generalities

### Mental generals

She was very gentle and polite in nature but fearful and anxious and always looking for company of known persons.

### Physical generals

Thermal reaction: hot<sup>+++</sup> (prefers winter); desire: rice<sup>++</sup>, vegetables<sup>++</sup>, salty things<sup>+</sup>; aversion: meat<sup>+++</sup>, sweets<sup>+</sup>; stool: normal, once/daily, bowel clear habit; urine: normal; perspiration: profuse especially upper part of the body, nonoffensive, nonstained on clothes; sleep: good.

On detailed case taking and analysis, the symptoms were evaluated to construct the totality. After evaluation of symptoms, repertorization was done. The following characteristic mental general symptoms, as well as physical general and particular symptoms, were considered for repertorization:

- Mild, gentle, polite in nature
- Fear of death
- Fear in crowd



dispensed to the patient from DACRRIH dispensary. Medicine was collected from Hahnemann Publishing Company Pvt. Ltd., which was a GMP certified ISO.9001:2008 unit.

## FOLLOW-UP AND OUTCOME

Treatment was done periodically with single medicine *Puls. nigricans* with increasing higher potencies (30, 200,

1M, 10M) according to response over the 15<sup>th</sup> month. Potency changes and repetition were done, following the homoeopathic principles and the second prescription of Kentian philosophy.<sup>[14,15]</sup>

Clinical follow-up was done in every month, and sonological evaluation was done at an interval of about 6 months. Sonomammography was done three times during the period of follow-up, which showed progressive reduction of FA size from baseline 3.48 cm × 2.38 cm on August 28, 2014; 2.06 cm × 1.4 cm on January 10, 2015 [Figure 2]; 1.77 cm × 0.82 cm on May 09, 2015 [Figure 3]; and finally 0.94 cm × 0.67 cm on November 19, 2015 [Figure 4].

In the initial 9 months of treatment from September 03, 2014, to May 15, 2015, FA was reduced to half in size (3.48 cm × 2.38 cm to 1.77 cm × 0.82 cm) which was assessed sonologically [Figure 3]. Then, over next 3 months, the case was followed up by placebo. However, there was no further reduction of size and improvement of other symptoms became standstill. In expectation of further reduction of size of FA, the next higher potency of same medicine, *Puls. nigricans* 10M, was prescribed on August 25, 2015, and October 23, 2015. Then, improvement was found in regression of FA, as well as in other symptoms such

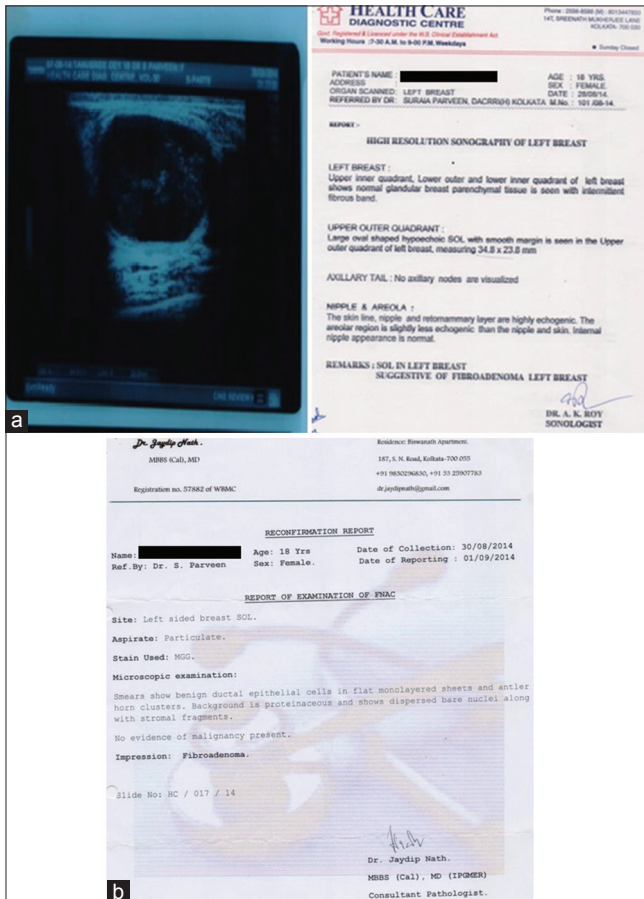


Figure 1: (a) Ultrasonography report of the left breast on August 28, 2014 (baseline), (b) fine-needle aspiration cytology report

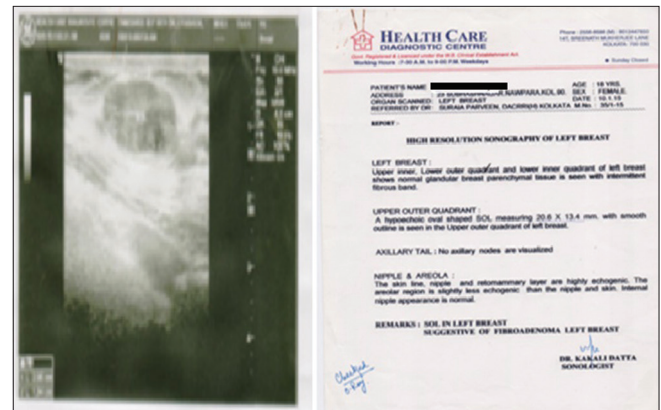


Figure 2: Ultrasonography report of the left breast on January 10, 2015 (during treatment)

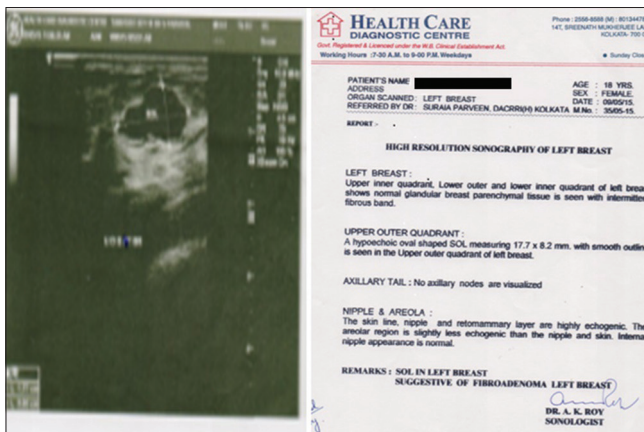

Figure 3: Ultrasonography report of the left breast on May 09, 2015 (during treatment)

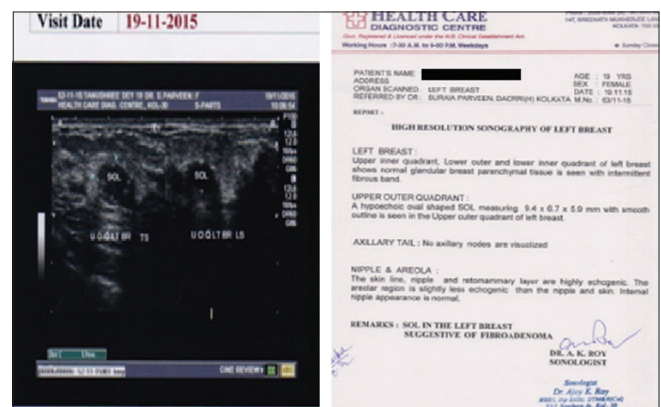


Figure 4: Ultrasonography report of the left breast on November 19, 2015 (longitudinal sections and transverse sections), after treatment

**Table 2: Detailed account of prescriptions and follow-up**

Date	Symptoms	Medicine with doses
03/09/14	Base line presentation Size of breast fibroadenoma – 3.48 x 2.38 cm [Figure 1A]	<i>Puls. nig</i> 30 BD (twice daily) x 2 days
20/09/14	No new symptoms and no aggravation, Not reduced the breast lump size and other mental anxiety symptoms but physical symptoms like pain during menses less, vomiting in riding car decreased	Placebo 30 BD x 15 days
15/10/14	No reduction of size of FA (on palpable) and mental anxiety symptoms, but menstrual pain and vomiting in car were increased than earlier	<i>Puls. nig</i> 30 BD x 2 days
30/10/14	Size of the breast lump reduced on palpation, menstrual pain less, Severity of headache reduced, vomiting during motion and mental anxiety-not relieved	Placebo 30 BD x 21 days
20/11/14	Clinically size of breast lump slightly reduced but no further improvement in other symptoms	Placebo 30 BD x 21 days
05/12/14	No further reduction of size of FA and improvement was same in mental and physical symptoms since last follow up. For further expectation of improvement the next higher potency of medicine was	<i>Puls. nig</i> 200 BD x 2 days
30/12/14	Reduction of size of FA than earlier, reduced mental anxiety symptoms like fear of death, less menstrual pain, other symptoms were same	Placebo 30 BD x 15 days
15/01/15	Clinically and sonologically (On 10.01.15), the size of FA reduced. Size – 2.06 x 1.4 cm [Figure 2]	Placebo 200 BD x 21 days
30/01/15	Mental anxiety symptoms and physical symptoms were improving. Feeling better in general Same as earlier in size of FA and other symptoms	Placebo 200 BD x 21 days
18/02/15	No further improvement in reduction of FA size and other mental and physical symptoms. Improvement was standstill	<i>Puls. nig</i> 200 OD (once daily) x 2 days
28/02/15	No any improvement was found in reduction of size (clinically), anxiety with fear was improved, menstrual pain and frequency of vomiting on motion less but persist	Placebo 200 BD x 15 days
10/03/15	Not further reduction FA size, No further improvement in other symptoms	Placebo 200 BD x 15 days
23/03/15	No any improvement was found in reduction of size (clinically) and menstrual pain was increased, others symptoms –no improved further	<i>Puls. nig</i> 1M OD x 2 days
13/04/15	Clinically, size of FA reduced than earlier, other symptoms were also improving	Placebo 1M BD x 21 days
30/04/15	FA size reduced on palpation, other symptoms were improving	Placebo 1M BD x 15 days
15/05/15	Clinically and sonologically (on 09.05.15), FA was reduced in size in half from base line measuring 1.77 x 0.82 cm [Figure 3] Other symptoms are improving	Placebo 1M BD x 21 days
06/06/15	No further reduction of FA in size and improvement of other symptoms	Placebo 1M BD x 21 days
24/06/15	No further reduction of FA since last two months and other symptoms dysmenorrhoea, mental anxiety, vomiting symptoms were not improved further	<i>Puls. nig</i> 1M OD x 2 days
16/07/15	No further improvement of reduction of FA size but the mental anxiety and vertigo with vomiting during car riding (motion sickness) were aggravated for first 3-4 days of taking of medicine. After that period then the gradual improvement was found for the above symptoms	Placebo 1M BD x 21 days
01/08/15	Clinically, size of FA was not regressed further. Other symptoms were not improved further	Placebo 1M BD x 21 days
25/08/15	No further improvement in regression of FA (clinically) and other symptoms. Improvement was standstill	<i>Puls. nig</i> 10M BD x 21 days
15/09/15	Clinically, size of FA was less than earlier, Other symptoms were improving also	Placebo 10M BD x 21 days
01/10/15	Clinically FA size was same, & other symptoms were improving	Placebo 10M BD x 15 days
12/10/15	No further regression of FA size and other symptoms were not improved further	Placebo 10M BD x 15 days
23/10/15	Not further regression of FA since last two follow up and other symptoms were same, feels not better in general. Same potency repeated in expectation of further reduction of size FA and improvement	<i>Puls. nig</i> 10M OD x 2 days
16/11/15	On palpation, the FA was reduced in size than earlier, other mental and physical symptoms were also improved, feeling better in general	Placebo 10M BD x 7 days

Contd...

**Table 2: Contd...**

Date	Symptoms	Medicine with doses
21/11/15	Clinically and sonologically (on 19.11,15), the size of FA was regressed significantly Size of FA –0.94 x 0.67 cm [Figure 4] Improvement was stable in all domains in general	Placebo 10M BD x 20 days
07/12/15	Size of FA was reduced gradually, never size increased (relapse) during the course of treatment and improvement was stable in other physical and psychological symptoms	Placebo 10M OD x 15 days
18/12/15 (recent status)	Significantly regressed FA with stable improvement in all domains	

**Table 3: Assessment by Modified Naranjo Criteria score**

Item	Yes	No	Not sure/N/A
Was there an improvement in the main symptom or condition for which the homoeopathic medicine was prescribed?	+2		
Did the clinical improvement occur within a plausible time frame relative to the drug intake?	+1		
Was there an initial aggravation of symptom? (need to define in glossary)	+1		
Did the effect encompass more than the main symptom or condition, i.e., were other symptoms ultimately improved or changed?	+1		
Did overall wellbeing improve? (suggest using validated scale)	+1		
Direction of cure: did some symptoms improve in the opposite order of the development of symptoms of the disease?			0
Direction of cure: did at least two of the following aspects apply to the order of improvement of symptoms -from organs of more importance to those of less importance - from deeper to more superficial aspects of the individual - from the top downwards			
Did old symptoms (defined as non-seasonal and non-cyclical that were previously thought to have resolved) reappear temporarily during the course of improvement?		0	
Are there alternate causes (other than the medicine) that-with a high probability- could have caused the improvement? (consider known course of disease, other forms of treatment and other clinically relevant intervention)		+1	
Was the health improvement confirmed by any objective evidence? (e.g. lab test, clinical observation, etc.)	+2		
Did repeat dosing, if conducted, create similar clinical improvement?	+1		

as anxiety in crowd with fear of death, dysmenorrhea, and motion sickness. Finally, there was nearly 75% regression in size (3.48 cm × 2.38 cm to 0.94 cm × 0.67 cm) of FA becoming almost nonpalpable [Figures 2-4 and Table 2].

The final outcome and possible causal attribution of the changes in this case were assessed using the “Modified Naranjo Criteria” as proposed by HPUS Clinical data Working Group (December 2015) [Table 3].<sup>[16]</sup>

The total score of outcome in this case was ten which was close to the maximum score of 13 as per Modified Naranjo Criteria.

## DISCUSSION

In this report, it was a confirmed case of simple FA in adolescence with no family history of malignancy. Thus, conservative management was appropriately considered and kept under observation for more than 12 months by the treating surgeon. However, this case does not fall under those categories of FA showing spontaneous regression and had progressive increase in size and thus had been advised to get operated by surgery before coming to homoeopathic treatment. Patient’s choice for homoeopathic treatment was guided by the factors such as fear of surgery, scar mark over the breast, and family history of FA which showed recurrence

after surgery and finally positive response on homoeopathic treatment.

In this case, *Puls. nigricans* was selected as a *Similimum* on the totality of characteristics symptoms assessed on mental and physical aspects, which was given more priority than the pathological diagnosis of soft tissue tumor. *P. nigricans* with subsequent higher potencies from 30C to 10M was prescribed according to the response of the medicine, which follows the principles of Homoeopathy and second prescription of Kentian philosophy. Finally, the treatment outcome of 75% regression in size of FA making it clinically almost nonpalpable was highly satisfactory. The total score of outcome as per Modified Naranjo Criteria was 10 in this case, which was close to the maximum score of 13. This explicitly shows the causal attribution of the single medicine homoeopathic treatment *Puls. nigricans* toward regression of the FA in this case.

Thus, the outcome of this case of FA in an adolescent girl indicates the usefulness of the homoeopathic treatment.

In previous study,<sup>[9]</sup> homoeopathic treatment had shown positive results on breast lesions and the three homoeopathic medicines *Calcarea carbonica*, *Natrum muriaticum*, and *Pulsatilla nigricans* were found to be most effective in the treatment of breast lesions. This has been corroborated in this case.

Significant regression in the size of FA along with improvement in other mental symptoms (anxiety in crowd with fear of death) and physical symptoms (dysmenorrhea, headache, motion sickness, vomiting) on an individualized single homoeopathic medicine reestablishes the holistic concept of Homoeopathy.

## CONCLUSION

- This case shows the positive role of homoeopathic treatment in simple FA which failed to show spontaneous regression
- It reconfirms the importance of individualized homoeopathic treatment based on holistic basis, rather than particular pathological diagnosis
- It may also suggest that the constitutional homoeopathic treatment may be given preference over surgical intervention as the first-line of treatment in spontaneously nonregressing FA cases in young women.

## Financial support and sponsorship

Nil.

## Conflicts of interest

None declared.

## REFERENCES

1. Foster ME, Garrahan N, Williams S. Fibroadenoma of the breast: A clinical and pathological study. *J R Coll Surg Edinb* 1988;33:16-9.
2. Hughes LE, Mansel RE, Webster DJ. Aberrations of normal development and involution (ANDI): A new perspective on pathogenesis and nomenclature of benign breast disorders. *Lancet* 1987;2:1316-9.
3. Williamson ME, Lyons K, Hughes LE. Multiple fibroadenomas of the breast: A problem of uncertain incidence and management. *Ann R Coll Surg Engl* 1993;75:161-3.
4. Soini I, Aine R, Lauslahti K, Hakama M. Independent risk factors of benign and malignant breast lesions. *Am J Epidemiol* 1981;114:507-14.
5. Cole-Beuglet C, Soriano RZ, Kurtz AB, Goldberg BB. Fibroadenoma of the breast: Sonomammography correlated with pathology in 122 patients. *AJR Am J Roentgenol* 1983;140:369-75.
6. Lee M, Soltanian HT. Breast fibroadenomas in adolescents: Current perspectives. *Adolesc Health Med Ther* 2015;6:159-63.
7. Greenberg R, Skornick Y, Kaplan O. Management of breast fibroadenomas. *J Gen Intern Med* 1998;13:640-5.
8. Moilola MR, Brodie KJ, Roohanie J. The efficacy of *Phytolacca decandra* in the treatment of fibroadenoma of the breast. *Am J Homeopath Med* 2006;99:116-9.
9. Gupta G, Naveen G, Madhu C. Fibroadenoma of breast: A sonomammographical supported clinical study on the effect of homoeopathic drugs. *Homeopathy* 2013;4:37-45.
10. Shah JJ. *Homopath Classic M.D Repertory*. Ver. 8.0. Mumbai, India: Mind Technologies Pvt. Ltd.; 2002.
11. Speight P. *A Comparison of the Chronic Miasms, Psora, Pseudopsora, Syphilis, Sycosis*. Reprint Edition. New Delhi: B. Jain Publishers (P) Ltd.; 1998. p. 1-87.
12. Boericke W. *Pocket Manual of Homoeopathic Materia Medica and Repertory*. 51<sup>st</sup> Impression. New Delhi: B. Jain Publishers (P) Ltd.; 2011. p. 536-9.
13. Allen HC. *Keynotes and Characteristics with Comparisons of Some of the Leading Remedies of the Materia Medica with Bowel Nosodes*. Reprint Edition. New Delhi: B. Jain Publishers (P) Ltd.; 2004. p. 235-7.
14. Hahnemann S. *Organon of Medicine*. 6<sup>th</sup> ed. New Delhi: B. Jain Publishers (P) Ltd.; 2011.
15. Kent JT. *Lectures on Homoeopathic Philosophy*. New Delhi: B. Jain Publishers (P) Ltd.; 2011. p. 231-41.
16. Van Haselen RA. Development of a supplement (HOM-CASE) to the CARE clinical case reporting guideline. *Complement Ther Med* 2016;25:78-85.