

Holistic treatment of chronic myeloid leukaemia with adjuvant homoeopathic therapy: A case report

Shaji Kumar R. T.*

Central Council for Research in Homoeopathy, New Delhi, India

Abstract

Introduction: Chronic myeloid leukaemia (CML) is a clonal myeloproliferative disorder of haematopoietic stem cell. **Case Summary:** This is a case of a 28-year-old female having CML for 1½ years, on regular allopathic medication. The patient was suffering from ulceration in the oral cavity, frequent offensive loose stools with melena and prolonged menstrual cycle with heavy bleeding for 3 weeks. After analysing the constitutional make-up of the patient, *Platinum metallicum* 200C was prescribed. Over a period of 3 months, the patient reported improvement in weakness, nausea, sleeplessness, irritability, heavy menstruation, loose black stools and backache. Until the last follow-up while submitting this report, the patient was on the maintenance dose of Imatinib along with homoeopathic medication.

Keywords: Cancer, Chronic myeloid leukaemia, Homoeopathy, Imatinib, *Platinum metallicum*

INTRODUCTION

Chronic myeloid leukaemia (CML) is a clonal myeloproliferative disorder of haematopoietic stem cell (HSC).^[1] Multiple haematopoietic cell lineages i.e., erythroid, myeloid, B cells and occasionally T cells express Bcr-Abl protein in most CML patients, indicating the presence of this oncogene in HSCs. The strongest evidence of monoclonality of CML was proved in a female patient with X-chromosome linked heterozygote alleles. CML was demonstrated as a clonal disorder being originating from single-unit multipotent stem cells of bone marrow.^[2,3]

The incidence of CML is 1–2 patients per million per year affecting individuals of all age groups. However, the median age of disease onset is estimated at 45–55 years.^[4,5] CML accounts for 20% of all leukaemias in adult patients. One of the characteristic findings in CML patients is the presence of the Philadelphia chromosome and Bcr-Abl (recombinant protein of human breakpoint cluster region-Abelson murine leukaemia viral oncogene) gene re-arrangement. Philadelphia is the shortened chromosome 22, formed by reciprocal translocation between the long arms of chromosomes 9 and 22.^[5,6] Philadelphia chromosome is found in 95% of CML patients, 5% of children and 15%–30% of adults with acute lymphoid leukaemia. In addition, it is also reported in 2% of diagnosed acute myeloid leukaemia patients.^[7]

Reciprocal translocation between the long arms of chromosomes 9 and 22 results in the fusion of Bcr-Abl on Philadelphia chromosome. Bcr-Abl gene expresses protein that effects cell growth, turnover, differentiation, adhesion and apoptosis. Abl (Abelson kinase) gene is located on chromosome 9. Abl gene has 11 exons with a molecular weight of 230 kilo base (kb). The upstream exon 2 is usually the breaking point in Abl gene.^[8]

CML has three phases. The chronic phase (CP) is most frequent, followed by the accelerated phase (AP) and blast crisis (BC). CP-CML can easily be managed with great cure rate. Additional genetic aberrations of leukemic stem cells result in its progression to AP-CML and BC-CML which are very difficult to manage. These additional genetic chromosomal aberrations can be identified by cytogenetic analysis. Yet, still other genetic changes do occur in stem cells of patients with CML but are not identifiable with the current laboratory testing.^[9]

***Address for correspondence:** Dr. Shaji Kumar R. T.,
Central Council for Research in Homoeopathy, New Delhi, India.
E-mail: shajikumar2016@gmail.com

Received: 05.09.2019; **Accepted:** 20.02.2020; **Published:** 09.04.2020.

Access this article online

Quick Response Code:



Website:
www.ijrh.org

DOI:
10.4103/ijrh.ijrh_49_19

This is an open access journal, and articles are distributed under the terms of the Creative Commons Attribution-NonCommercial-ShareAlike 4.0 License, which allows others to remix, tweak, and build upon the work non-commercially, as long as appropriate credit is given and the new creations are licensed under the identical terms.

For reprints contact: reprints@medknow.com

How to cite this article: Shaji Kumar RT. Holistic treatment of chronic myeloid leukaemia with adjuvant homoeopathic therapy: A case report. *Indian J Res Homoeopathy* 2020;14:50-6.

Patients with CML in CP may be asymptomatic, or symptoms may appear before the treatment due to changes in blood cell counts or splenomegaly may be present. CP-CML may resolve promptly once patients are treated effectively. Complications such as infections and bleeding are uncommon during CP-CML. Once treated successfully, patients with CP-CML are completely normal for performing daily life activities.^[10]

AP-CML phase if develops may cause fatigue, lethargy and weight loss. Leucocytes may either be very low or high due to the pooling of blast cells. Platelets usually decrease in number. Blast cell counts increase in the peripheral blood and bone marrow. Splenomegaly may be present; the patients become weak with low haemoglobin (Hb). Bleeding and infections are common in the phase. The general well-being of the patient is lost.^[11]

During BC, excessive blast cells are pooled in the peripheral circulation and bone marrow. Red cells, neutrophils and platelets are very low. Severe infections are common, and bleeding tendency occurs. Patients complain of generalised weakness, fatigue, dyspnoea, bone pain, abdominal pain and splenomegaly. BC resembles acute leukaemia regarding clinical signs and symptoms.^[12] In 25% of patients, transformation of BC culminates into acute lymphoblastic leukaemia, while in the remaining cases, it progresses to acute myeloid leukaemia. CP-CML is characterised by elevated number of myeloid progenitor and mature cells in the peripheral blood and bone marrow.^[13] Quantitative reverse transcriptase-polymerase reaction-mediated detection mRNA of Bcr-Abl and visualisation of Bcr-Abl oncogene by double-fusion fluorescent *in situ* hybridisation also make the diagnosis definite.^[14]

If not treated, CP-CML progresses to AP and BC-CML over 3–5 years of onset.^[15] It may take several weeks or months for the transformation of CP-CML into AP and BC-CML.²⁰ Differentiation of cells becomes blocked in later stages; blast cells accumulate in the bone marrow and blood; at this stage, it resembles acute leukaemias.^[16]

Additional cytogenetic abnormalities appear as disease progresses to BC-CML.^[17] BC-CML transformation may be lymphoid, myeloid or both and carries very poor prognosis.^[18] The median survival time for patients with acute blast cell crisis in CML is 4–5 months and 12 months, respectively.^[19] Imatinib mesylate, a selective Bcr-Abl tyrosine kinase inhibitor introduced in the 1990s, has revolutionised the treatment and prognosis of CML. With long-term follow-up, the solid benefits of Imatinib therapy are sustained; the 7-year estimated incidence of durable cytogenetic response is approximately 70%, the estimated 7-year survival is close to 90% and 94% if only CML-related deaths are counted. Among patients who present with accelerated or blastic-phase CML, or who develop Imatinib resistance, allogenic stem cell transplant, second-generation tyrosine kinase inhibitors and Imatinib combinations are the treatment options.^[20] Sporadic literature

and case records about the use of Homoeopathy in the treatment of CML are available. However, due to lack of evidence in support of the usefulness of homoeopathic treatment, it is not worth mentioning.

CASE REPORT

History

A 28-year-old female (homemaker by occupation), hailing from Kasba, Uttar Pradesh, a known case of CML, was admitted to Delhi State Cancer Institute and Hospital (DSCI) on 6 September 2018 for the complaint of ulceration in the oral cavity, frequent offensive loose stools with melena and prolonged menstrual cycle with heavy bleeding for 3 weeks.

She was asymptomatic before 1½ years. Around this time, she developed hepatomegaly for which symptomatic treatment was taken from DSCI. Consequently, bone marrow aspiration cytology on 4 May 2017 suggested a diagnosis of CML-CP [Figure 1]. She was advised to take tablet Imatinib 400 mg/day. The patient discontinued treatment and consulted All India Institute of Medical Sciences, New Delhi. ABL1-tyrosine kinase domain mutation test conducted on 20 July 2018 was found negative and tablet Imatinib was prescribed as the drug of choice [Figure 2].

The patient reported in the allopathic private outpatient department on 20 November, 2018, with severe weakness, retrosternal burning, indigestion, nausea, metrorrhagia, melena and weakness of anal sphincter leading to escape of stool along with urine [Figure 3].

- Past history – No history of hypertension, diabetes mellitus and tuberculosis

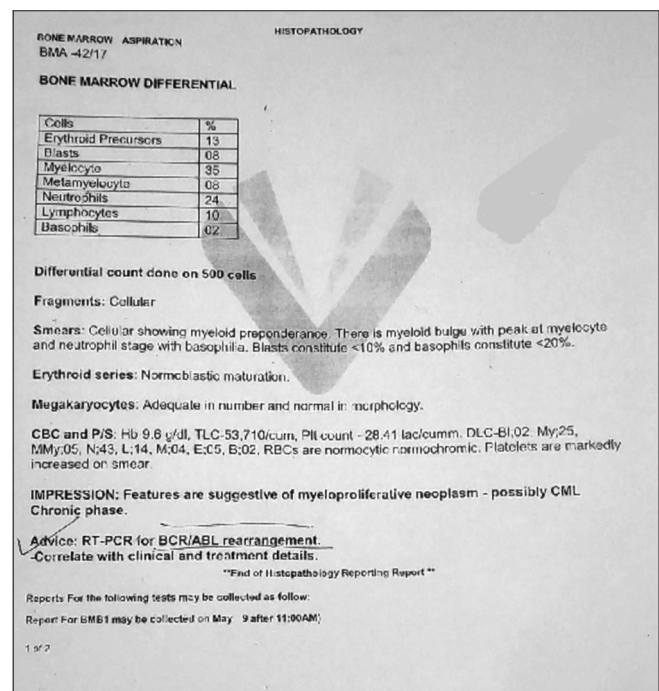


Figure 1: Diagnosis of chronic myeloid leukaemia

- Obstetric history – P4L3, youngest child was 2-year-old healthy male child
- Family history – No confirmed history of cancer in the family
- Clinical examination – Appearance – sickly, built – moderate, nutrition – moderately nourished, weight – 48.4 kg, pallor – ++, cyanosis – nil, clubbing – nil, jaundice – nil, oedema – nil, dyspnoea – nil, blood pressure – 110/70 mmHg.

To assess the condition of the patient, she was admitted and the following investigations were performed.

- Blood routine – Hb – 7.7 mg/dl, total leucocyte count – 2000/mm³, platelets – 30,000/mm³
- Peripheral blood film – Red blood cell (RBC) – microcytic hypochromic; polychromasia; tear drop cells; 1-2 RBC/100 white blood cells
- Bone marrow aspiration report – Cellularity: low cellular, megakaryocytes: seen, myelocytes: 4%, metamyelocytes: 8%, neutrophils: 8%, lymphocytes: 8%, blast cells: nil, plasma cells: nil, monocytes: 1%, eosinophils: 1%, erythroid cells: normoblastic 70%. ME ratio ~1:2.3
- Impression – Hypocellular bone marrow aspirate
- Bone marrow biopsy – Hypocellular bone marrow biopsy
- Ultrasonography dated 10 September 2018 revealed hepatomegaly
- HIV, HbSag, HCV – Non-reactive.

The patient was transfused with 6 units of platelet concentrate on 22 November 2018, followed by 4 units on 24 November 2018, 2 units on 27 November 2018 and 2 units on 2 December 2018. She was also given injection tranexa 1 amp. I/V × TDS, injection pantop 40 mg I/V × BD, injection fluconazole 1 amp. I/V × OD, injection metrogyl 1 amp. I/V × BD, injection intabolin I/M stat, tablet bescopan TDS, tablet prednisolone 20 mg × TDS.

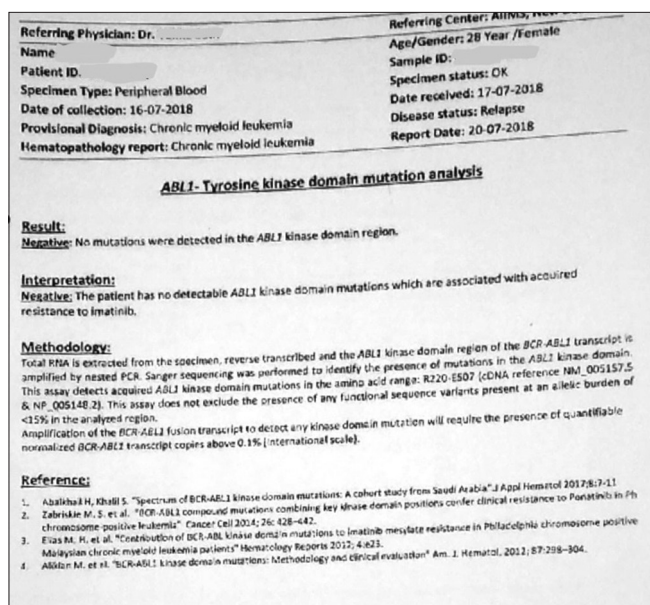


Figure 2: Tyrosine kinase mutation analysis report

The case was referred by the allopathic consultant to the homoeopathic unit on 29 November 2018 with the presenting complaints of ulceration in the mouth with painful swallowing, weakness, nausea, sleeplessness, irritability, heavy menstruation, loose black stools and backache.

History of presenting illness

The patient complained of colicky pain in the abdomen, resulting in watery, sticky black stools 4–5 times daily with itching in the anal area. Menstrual cycles were heavy with passage of black clotted blood. Occasional intermenstrual bleeding/leucorrhoea was also reported to occur. She had no desire to have food. Though tired, she was not able to sleep more than an hour in the night.

Examination

The oral mucosa was hyperemic with ulcers on the mucosa and tongue having yellow pus. The patient looked pale and exhausted.

Mental state of the patient

The patient repeated her complaints and pleaded to do something to save her from death. She told that her children are too young to settle down by themselves. She was not permitting her husband to go home to see their children for the fear of his death on the way. It was also noted that the patient was highly irritable and was verbally abusing her husband when he had attempted to narrate the details of her illness.

When talked to her husband separately, he told that the patient picks fights for trivial reasons and keeps abusing him throughout the day. She never accepts her mistakes and if pointed out, picks a verbal fight. At times, she appears very pleasant and happy but soon becomes angry on silly matters.

Repertorial totality

On analysis of the symptoms, the following rubrics were




Figure 3: Blood picture of 20 November 2018

considered and repertorised using Boericke's Clinical Repertory:^[21]

1. Mind: Death, fatal disease, impending evil
2. Mind: Fault finding, finicky, cautious
3. Mind: Haughty, arrogant, proud
4. Mind: Hysterical (changeable, vacillatory)
5. Stomach: Heartburn, pyrosis
6. Abdomen: Stools pasty, tenacious adhering to the anus
7. Abdomen: Black stools.

Based on the totality and repertorisation, homoeopathic medicine *Platinum metallicum* 200C (from a good manufacturing practice-certified pharmaceutical company) one dose was prescribed on 29 November 2018 along with *Saccharum Lactis* (SL) 3 pills × TDS × 1 day.

Follow-up and outcomes

Table 1 shows the details of the follow up from November 2018 to the most recent follow up. The patient said that, "I was in extreme weakness and was passing tarry sticky stools about 3–4 times daily and my periods also were lengthy and heavy.

I used to be tense and irritable. After the taking homoeopathic treatment, I feel much relaxed, eating and sleeping well, pleasant and my complaints are far better. I want to continue with Homoeopathic treatment to get rid of my remaining problems".

DISCUSSION

Imatinib is a powerful inhibitor of the tyrosine kinase activity of Bcr-Abl, the oncoprotein responsible for CML. The drug shows great efficacy in CP but is less effective in maintaining haematologic remissions in BC patients.^[22] Low blood counts, nausea and vomiting, oedema, muscle cramps and bone pain, diarrhoea, haemorrhage, skin rash and fever are the common side effects of Imatinib; the drug of choice in CML. The patient in focus also was on daily dosage of Imatinib 400 mg and was suffering from low blood counts, nausea and vomiting, muscle cramps and bone pain, diarrhoea, haemorrhage and fever. Hepatomegaly, anaemia and blood loss through bowels and uterus were persisting with this drug. Even after repeated transfusion of whole blood and components of blood, the blood

Table 1: Timeline of patient response and medicine prescribed with its dose

Date	Response	Prescription
30 November 2018	Weakness - Better, stool passed at 7 a.m. Stool black but not sticky as before. Sleep - disturbed due to fever at night. Retrosternal burning++ Patient is on daily dose of Imatinib 400 mg	SL 30 3 pills × TDS × 1 day
03 December 2018	No weakness, no fever, stools - yellow colour mixed with occasional brownish black colour. Well formed and nonsticky. Appetite: good. Retrosternal burning++ Irritability - Same, the patient is aggressive and abusive Platelet infusion was given on 02 December 2018 Blood report on 02 December 2018: Hb - 11.00 mg/dl, TLC - 1470/mm ³ , platelets - 32,000/mm ³ . The patient's irritability had no change. She was aggressive and abusive during the follow-up interaction. Her TLC on the previous day was 1470/mm ³ and platelets were 32,000/mm ³ . Therefore <i>Platinum metallicum</i> 200C one dose was prescribed on 03 December 2018	<i>Platinum metallicum</i> 200C one dose SL 30 three pills × TDS × 1 day
05 December 2018	Weakness - Nil, Fever - Nil, Stools - yellow colour, well formed. retrosternal burning >+ Blood report on 04 December 2018: Hb - 11.40 mg/dl, TLC - 2690/mm ³ , Platelets - 38,000/mm ³ The patient was discharged on 05 December 2018	SL 30 three pills × TDS × 1 day
11 December 2018	Acute rhinitis with continuous sneezing. Watery and occasional yellowish discharge from nose. Ailments - After exposure to cold water doing domestic works On Examination - Throat - no congestion, tongue mild white coating Had menstruation for the last 5 days. No heavy flow. Husband reported that irritability of patient under control. Frequency of verbal abuse and tantrums have reduced >90%	<i>Arsenicum album</i> 30 3 pills × BD × 3 days
31 December 2018	Complaint of fever for 6 days Fever with dryness of mouth and increased thirst During fever want to lie down still till temperature subsides Retrosternal burning with tendency to vomit. O/E - Tongue dry with white coating with patchy bald spots The patient is on maintenance dose of Imatinib 200 mg daily dose	<i>Bryonia alba</i> 30 three pills × TDS × 5 days
16 January 2019	Complaint of evening rise of temperature with sweat for 15 days. Loose profuse stools for 1 week Blood report on 03 January 2019: Hb - 12.8 g/dl, TLC - 5000/mm ³ , RBC - 3.94 million/mm ³ , platelets - 215,000 cells/mm ³ , ESR - 16 mm/1 h DLC: N - 58%, L - 35%, E - 4%, M - 1% <i>Salmonella typhi</i> - 1/160 titre	<i>Veratrum album</i> 30 3 pills × QID × 3 days <i>Ferrum phosphoricum</i> 30 three pills × SOS
20 February 2019	Fever - nil, Weakness - >+, complaint of retrosternal burning with occasional vomiting. Headache with yellow thick acrid leucorrhoea. The last menstrual cycle after 27 days lasted for 5 days. Flow - moderate. Stools - well formed. Appetite - good, Sleep - good; 7-8 h. Irritability has increased in the last 2 weeks	<i>Pulsatilla</i> 30 three pills × SOS <i>Platinum metallicum</i> 200 1 dose (to be taken after the acute episode) SL 30 three pills × BD × 1 month

Hb: Haemoglobin, TLC: Total Leucocyte Count, ESR: Erythrocyte Sedimentation Rate, DLC: Differential Leucocyte Count, + or ++ = severity 1, +++ or ++++ = severity 2

Table 2: Assessment of outcome with modified Naranjo algorithm

Question	Yes	No	Not sure or N/A	Score
1. Was there an improvement in the main symptom or condition for which the homoeopathic medicine was prescribed?	+2	-1	0	+2
2. Did the clinical improvement occur within a plausible time frame relative to the drug intake?	+1	-2	0	+1
3. Was there an initial aggravation of symptoms? (need to define in glossary)	+1	0	0	0
4. Did the effect encompass more than the main symptom or condition i.e., were other symptoms ultimately improved or changed?	+1	0	0	+1
5. Did overall well-being improve? (suggest using validated scale)	+1	0	0	+1
6. (B) Direction of cure: Did at least two of the following aspects apply to the order of improvement of symptoms: From organs of more importance to those of less importance From deeper to more superficial aspects of the individual From the top downwards	+1	0	0	+1
7. Did 'old symptoms' (defined as non-seasonal and non-cyclical symptoms that were previously thought to have resolved) reappear temporarily during the course of improvement?	+1	0	0	0
8. Are there alternate causes (other than the medicine) that - with a high probability - could have caused the improvement? (consider known course of disease, other forms of treatment and other clinically relevant interventions)	-3	+1	0	+1
9. Was the health improvement confirmed by any objective evidence? (e.g., lab test, clinical observation, etc.)	+2	0	0	+2
10. Did repeat dosing, if conducted, create similar clinical improvement?	+1	0	0	+1
Total score				+10

N/A: Not available

picture was not returning to normalcy. To assess the causal attribution to the homoeopathic therapy, modified Naranjo algorithm was applied in this case [Table 2].

The patient was suffering from weakness, retrosternal burning, indigestion, nausea, metrorrhagia, melena, weakness of anal sphincter leading to escape of stool along with urine, frustration causing irritability, anxiety about her family and children's future and fear of death from the time of diagnosis of illness. Unfortunately, no one paid attention to her mental agony and the standard treatment protocol had no place for her ordeal.

Despite 14-unit platelet transfusion between 22 November 2018 and 2 December 2018, the platelet count remained poor as per the blood report on 3 December 2018. Patient was also suffering from persisting weakness, anaemia, loss of appetite and sleep. Introduction of homoeopathic constitutional medicine has improved her general condition by increase in oral intake, reduction on irritability, better sleep and reduction in weakness. From the very next day of the prescription of *Platinum metallicum* 200C, the patient reported that the colour and stickiness of the stool has changed and there was substantial reduction in weakness. The prescription of *Platinum metallicum* was finalised mainly on the mental features along with physical symptoms such as black tarry sticky offensive stools and menstrual characters. The patient required infrequent repetition of three doses of *Platinum metallicum* 200C in a period of 3 months to have relief from the long-standing issues of weakness, anaemia, loss of appetite, retrosternal burning, indigestion, nausea, metrorrhagia, melena, weakness of anal sphincter leading to escape of stool along with urine, irritability, etc., It is also

appreciable that the patient did not have any blood transfusion for the last 3 months and no hospitalisation since her vital signs are close to normal and leading a normal routine. The patient was on 400-mg Imatinib on a daily basis from the diagnosis of the illness and is now on maintenance dose of 200 mg from 13 December 2018 along with homoeopathic adjuvant therapy. Therefore, it is observed that, reduction in days of hospitalisation due to CML, side effects of conventional therapy, tapering of conventional therapy and costs involved in the hospitalisation and treatment can be effectively managed through homoeopathic constitutional treatment.

CONCLUSION

Homoeopathy can play key role in supportive care and as integrative medicine in offering safe, and effective way of managing chronic illness such as CML and to combat the side effects of conventional therapy. It may also be helpful to reduce the days of hospitalisation and can significantly improve therapy outcomes as well as patient's quality of life. Further research in this area is required to ascertain the efficacy of constitutional homoeopathic adjuvant therapy in such cases.

Declaration of patient consent

The author certifies that he has obtained informed verbal consent from patient for her images and other clinical information to be reported in the journal. The patient understands that her name and initials will not be published and due efforts will be made to conceal identity, but anonymity cannot be guaranteed.

Financial support and sponsorship

Nil.

Conflicts of interest

None declared.

REFERENCES

- American Cancer Society. Cancer Facts and Figures; 2008. Available from: <http://google.com/>. [Last accessed on 2019 Mar 22].
- Barret KE, Barman SM, Boitano S, Brooks H. Ganong's Review of Medical Physiology. 24th ed. McGraw Hill Medical Publishing; 2012. p. 507-8.
- Guyton AC, Hall JE. Textbook of Medical Physiology. 11th ed. Philadelphia, Pennsylvania: Elsevier Saunders; 2012. p. 457-60.
- Hoffbrand AV, Moss PA, Pettit JE. Essential Hematology. 5th ed. USA: Blackwell Publishing; 2012. p. 1435.
- National Cancer Institute's Surveillance, Epidemiology and End Results (SEER); 2011. Available from: <http://seer.cancer.gov>. [Last accessed 2017 Nov 29].
- Available from: <https://www.ncbi.nlm.nih.gov/pubmed/29633732>. [Last accessed on 2019 Mar 22].
- Blot WJ, Henderson BE, Boice JD Jr. Childhood cancer in relation to cured meat intake: Review of the epidemiological evidence. *Nutr Cancer* 1999;34:111-8.
- Thompson JR, Gerald PF, Willoughby ML, Armstrong BK. Maternal folate supplementation in pregnancy and protection against acute lymphoblastic leukaemia in childhood: A case-control study. *Lancet* 2001;358:1935-40.
- Smith DL, Burthem J, Whetton AD. Molecular pathogenesis of chronic myeloid leukaemia. *Expert Rev Mol Med* 2003;5:1-27.
- Vardiman JW, Harris NL, Brunning RD. The World Health Organization (WHO) classification of the myeloid neoplasms. *Blood* 2002; 100:2292-302.
- Nowell PC, Hungerford DA. A minute chromosome in human chronic granulocytic leukemia. *Science* 1960;132:1497.
- Rowley JD. Letter: A new consistent chromosomal abnormality in chronic myelogenous leukaemia identified by quinacrine fluorescence and Giemsa staining. *Nature* 1973;243:290-3.
- Groffen J, Stephenson JR, Heisterkamp N, Bartram C, de Klein A, Grosveld G. The human c-abl oncogene in the Philadelphia translocation. *J Cell Physiol Suppl* 1984;3:179-91.
- Elefanti AG, Hariharan IK, Cory S. Bcr-abl, the hallmark of chronic myeloid leukaemia in man, induces multiple haemopoietic neoplasms in mice. *EMBO J* 1990;9:1069-78.
- Kelliher MA, McLaughlin J, Witte ON, Rosenberg N. Induction of a chronic myelogenous leukemia-like syndrome in mice with v-abl and BCR/ABL. *Proc Natl Acad Sci U S A* 1990;87:6649-53.
- Pear WS, Miller JP, Xu L, Pui JC, Soffer B, Quackenbush RC, et al. Efficient and rapid induction of a chronic myelogenous leukemia-like myeloproliferative disease in mice receiving P210 bcr/abl-transduced bone marrow. *Blood* 1998;92:3780-92.
- Reuther GW, Fu H, Cripe LD, Collier RJ, Pendergast AM. Association of the protein kinases c-Bcr and Bcr-Abl with proteins of the 14-3-3 family. *Science* 1994;266:129-33.
- McWhirter JR, Galasso DL, Wang JY. A coiled-coil oligomerization domain of Bcr is essential for the transforming function of Bcr-Abl oncoproteins. *Mol Cell Biol* 1993;13:7587-95.
- Pendergast AM, Muller AJ, Havlik MH, Maru Y, Witte ON. BCR sequences essential for transformation by the BCR-ABL oncogene bind to the ABL SH2 regulatory domain in a non-phosphotyrosine-dependent manner. *Cell* 1991;66:161-71.
- Holland JF, Frei E, Hong WK, Bast RC Jr., Hait WN, Kufe DW, et al. *Cancer Medicine*. 8th ed. USA: People's Medical Publishing House; 2010. p. 1585.
- Boericke W. *New Manual of Homeopathic Materia Medica with Repertory: Third Revised and Augmented Edition Based on Ninth Edition*; 2007.
- Available from: <https://www.drugbank.ca/drugs/DB00619>. [Last accessed on 2019 Mar 19].

पुरानी माइलॉयड ल्यूकेमिया का समग्र उपचार होम्योपैथी चिकित्सा के साथ: एक मामले का विवरण

परिचय: पुरानी माइलॉयड ल्यूकेमिया (सीएमएल) हिमेटोपोएटिक स्टेम सेल (एचएससी) का एक प्रतिरूप माइलोप्रोलिफेरेटिव विकार है। **सारांश:** यह एक 28 वर्षीय महिला का मामला है, जिसे पुरानी माइलायड ल्यूकेमिया है जो डेढ़ साल से नियमित रूप से एलोपैथिक (इमेटिनिब) दवा का सेवन कर रही है। रोगी 3 सप्ताह से भारी रक्तस्राव के साथ मौखिक गुहा में ब्रणोत्पत्ति, मेलेना के साथ लगातार ढीला मल और लंबे समय तक मासिक धर्म चक्र से पीड़ित थी। रोगी के संवैधानिक ढांचे का विश्लेषण करने के बाद होम्योपैथिक दवा प्लैटिनम-मेटालिकम 200 सी निर्धारित की गई थी। 3 महीने की अवधि में, रोगी ने कमजोरी, मतली, नींद न आना, चिड़चिड़ापन, भारी मासिक धर्म, ढीले काले मल और पीठ दर्द में सुधार का विवरण दिया। अंतिम अनुवर्ती तक, इस विवरण को प्रस्तुत करते समय, रोगी होम्योपैथिक दवा के साथ इमेटिनिब की खुराक लेती थी।

Traitement holistique des cas de leucémie myéloïde chronique avec traitement adjuvant homéopathique: un rapport de cas

Introduction: La leucémie myéloïde chronique (LMC) est un trouble myéloprolifératif clonal des cellules souches hématopoïétiques (CSH). **Résumé du cas:** Il s'agit du cas d'une femme de 28 ans atteinte de LMC depuis un an et demi, sous médication allopathique régulière. La patiente souffrait d'ulcérations dans la cavité buccale, de selles molles offensives fréquentes avec méléna et d'un cycle menstruel prolongé avec saignements abondants depuis 3 semaines. Après avoir analysé la constitution du patient, du *Platinum metallicum* 200C a été prescrit. Sur une période de 3 mois, le patient a signalé une amélioration de la faiblesse, des nausées, des insomnies, de l'irritabilité, des menstruations abondantes, des selles noires molles et des maux de dos. Jusqu'au dernier suivi lors de la soumission de ce rapport, le patient recevait la dose d'entretien d'Imatinib avec des médicaments homéopathiques.

Tratamiento holístico de un caso de leucemia mieloide crónica con un tratamiento homeopático coadyuvante: informe de caso clínico

Introducción: La leucemia mieloide crónica (LMC) es un trastorno mieloproliferativo clonal de las células madre hematopoyéticas (CMH).

Resumen del caso: Se trata de una mujer de 28 años con LMC desde hacía año y medio y sometida a medicación alopática regular. La paciente presentaba una ulceración en la cavidad oral, frecuente deposición de heces sueltas ofensivas con melena y ciclo menstrual prolongado con abundante sangrado desde hacía 3 semanas. Tras analizar la constitución de la paciente, se le prescribió *Platinummetallicum* 200C. Durante un periodo de 3 meses, fueron mejorando la debilidad, las náuseas, la irritabilidad, la menstruación pesada, las heces sueltas negras y el dolor de espalda. Hasta el último seguimiento al redactar este informe, la paciente recibía la dosis de mantenimiento de Imatinib junto con la medicación homeopática.

Ganzheitliche Behandlung eines Falles von chronisch-myeloischer Leukämie mit adjuvanter homöopathischer Therapie: ein Fallbericht

Einführung: Die chronisch-myeloische Leukämie (CML) ist eine klonale myeloproliferative Störung der hämatopoetischen Stammzellen (HSZ).

Fallzusammenfassung: Es handelt sich um den Fall einer 28-jährigen Frau, die seit anderthalb Jahren an CML leidet und regelmäßig allopathische Medikamente einnimmt. Die Patientin litt unter Geschwüren in der Mundhöhle, häufigem offensivem, lockerem Stuhlgang mit Melena und einem verlängerten Menstruationszyklus mit starken Blutungen seit 3 Wochen. Nach der Analyse der konstitutionellen Verfassung der Patientin wurde *Platinmetalum* 200C verschrieben. Über einen Zeitraum von 3 Monaten berichtete die Patientin über eine Verbesserung der Schwäche, Übelkeit, Schlaflosigkeit, Reizbarkeit, starke Menstruation, lockerem schwarzen Stuhl und Rückenschmerzen. Bis zur letzten Nachuntersuchung, als dieser Bericht eingereicht wurde, nahm der Patient die Erhaltungsdosis von Imatinib zusammen mit homöopathischen Medikamenten ein.

慢性骨髓性白血病個案，加入順勢療法輔助的整全治療：個案報告

引言：慢性骨髓性白血病（Chronic Myeloid Leukemia, CML）是造血幹細胞（hematopoietic stem cell, HSC）的克隆性骨髓增生性疾病。**個案總結：**這是一名28歲女士的個案，一年半前起患有慢性骨髓性白血病，有定期服用對抗療法藥物。3周前開始患者口腔潰瘍，頻繁惡臭的黑糞便瀉，月經周期延長，出血嚴重。在分析了病人的體質後，處方了鉑金200C。在3個月裏，病人報告虛弱、噁心、失眠、易怒、月經過多、黑糞便瀉和背痛有改善。在提交此報告時的最後一次跟進之前，患者一直服用維持用量的伊馬替尼（Imatinib）和順勢療法藥物。