

## Bleeding nasal polyp in a child, treated with individualised homoeopathy: A case report

Ranjit Sonny

Author(s) ORCID Identifier:

<https://orcid.org/0000-0002-1395-831X>

Follow this and additional works at: <https://www.ijrh.org/journal>



Part of the [Alternative and Complementary Medicine Commons](#)



---

## Bleeding nasal polyp in a child, treated with individualised homoeopathy: A case report

### Abstract

**Introduction:** A nasal polyp (NP) is a type of growth inside the nose or sinuses typically presenting with nasal congestion, nasal obstruction and anosmia or hyposmia. It is amenable to the individualised homoeopathic treatment. In this case, we present how an NP in a female child was successfully treated with individualised homoeopathy.

**Case Summary:** A case of NP in a 5-year-old female child presented to the outpatient department in November 2021. It was bleeding frequently, especially when hurt. It blocked the right nostril and was visible from the outside. *Acidum nitricum* (Acid-nit) was prescribed based on the totality of symptoms. After a few follow-ups, the patient started improving and the bleeding stopped. The size of the polyp also diminished gradually. Within 1 and ½ months of starting treatment, the polyp disappeared. This case is a testimony of the usefulness of homoeopathy in NPs. Further research could define the role of homoeopathy in the management of NPs.

# Bleeding nasal polyp in a child, treated with individualised homoeopathy: A case report

Ranjit Sonny\*

Regional Research Institute for Homoeopathy, Siliguri, West Bengal, India

## Abstract

**Introduction:** A nasal polyp (NP) is a type of growth inside the nose or sinuses typically presenting with nasal congestion, nasal obstruction and anosmia or hyposmia. It is amenable to the individualised homoeopathic treatment. In this case, we present how an NP in a female child was successfully treated with individualised homoeopathy. **Case Summary:** A case of NP in a 5-year-old female child presented to the outpatient department in November 2021. It was bleeding frequently, especially when hurt. It blocked the right nostril and was visible from the outside. *Acidum nitricum (Acid-nit)* was prescribed based on the totality of symptoms. After a few follow-ups, the patient started improving and the bleeding stopped. The size of the polyp also diminished gradually. Within 1 and ½ months of starting treatment, the polyp disappeared. This case is a testimony of the usefulness of homoeopathy in NPs. Further research could define the role of homoeopathy in the management of NPs.

**Keywords:** Homoeopathy, Individualised homoeopathy, Nasal polyp, Paediatric population

## INTRODUCTION

Nasal polyps (NPs) are benign inflammatory outgrowths causing chronic nasal obstruction, usually associated with underlying chronic rhinosinusitis (CRS), which is rarely reported in childhood.<sup>[1]</sup> NPs typically present with nasal congestion, nasal obstruction and anosmia or hyposmia. Morphologically, NPs are oedematous grape-like protrusions most often originating in the upper part of the nose around the stomatal complex on the lateral wall. NPs occur in 1–4% of the population, usually occurring in the setting of an underlying local or systemic disease and more frequent in patients aged 55–59 and 75–79 years. A high prevalence of NPs is also seen in allergic fungal rhinosinusitis, aspirin-exacerbated respiratory disease, Churg–Strauss syndrome and cystic fibrosis. In the setting of CRS, NPs are not likely to be cured by either medical or surgical therapy; however, control is generally attainable.<sup>[2,3]</sup>

Homoeopathy is a system based on the Law of Similars. Homoeopathic medicines not only helps in treating NPs, thereby avoiding surgery but also prevent the recurrence. There are many homoeopathic remedies such as *Acidum nitricum*, *Lemna minor*, *Teucrium marum varum*, *Calcarea Carbonicum* and *Phosphorus* which give relief to the NPs.<sup>[4]</sup> Apart from the above Samiuddin

and Hulekar advised 13 medicines with indications effective in this surgical condition.<sup>[5]</sup> Regarding miasmatic inclination, almost all the cases belong to either sycosis or dominantly tubercular miasm.<sup>[6]</sup> A brief description of the case is given below.

## PATIENT INFORMATION

A female child, aged 5 years, presented to the outpatient department (OPD) of Regional Research Institute for Homoeopathy, Siliguri in November 2021. She presented with a pea-sized swelling protruding from the right nostril. It was reported to bleed spontaneously on and off or when hurt. Before reporting to the OPD, the patient had visited the nearest government medical college for treatment. The surgeon there had diagnosed it as an NP. During case taking, the mother informed about an eruption that appeared in the right nostril 15 days ago. It did not heal and developed into an outgrowth. Gradually, bleeding from the growth started on

**\*Address for correspondence:** Ranjit Sonny,  
Regional Research Institute for Homoeopathy, Siliguri, Darjeeling - 734 011,  
West Bengal, India.  
E-mail: drranjitsonnymd@gmail.com

**Received:** 20 October 2022; **Accepted:** 04 December 2023

### Access this article online

#### Quick Response Code:

Available in print  
version only

**Website:**  
www.ijrh.org

**DOI:**  
10.53945/2320-7094.1282

This is an open access journal, and articles are distributed under the terms of the Creative Commons Attribution-NonCommercial-ShareAlike 4.0 License, which allows others to remix, tweak, and build upon the work non-commercially, as long as appropriate credit is given and the new creations are licensed under the identical terms.

**How to cite this article:** Sonny R. Bleeding nasal polyp in a child, treated with individualised homoeopathy: A case report. Indian J Res Homoeopathy 2023;17:249-254.

and off. This was a rare polyp, since it appeared in a child of 5 years age, and grew fast in size. The doctors had advised its surgical removal. The patient even underwent all the pre-surgical tests and was almost ready for surgery, but the mother was hesitant. She wanted to try homoeopathy once before the surgery.

### Clinical findings

On clinical examination, a pea-sized growth was seen hanging from inside the right nostril. The growth was soft in consistency and bled easily upon touching. Upon examination, the case was reconfirmed as a NP. Case taking was done as per homoeopathic guidelines. In the past history of the child, nothing remarkable was found but in family history, her grandfather suffered from tuberculosis.

The appetite of the child was good, and the thirst was normal. She desired sweets and meat. Her tongue had a white coating and a red tip. She passed urine often, more than the usual frequency. The stool was regular and semisolid. She had profuse sweat. The sleep was sound.

On the mental front, the patient was very irritable and revengeful. This was ascertained by the mother's narrative that upon being hit by other children, even during playing, she cannot stop herself from hitting back in revenge. Her mother said she also fought with her brother on silly matters.

### Diagnostic assessment

The case was diagnosed as an ethmoidal polyp based on the anterior rhinoscopy examination. Usually, the ethmoidal polyps are multiple and bilateral and arise from the ethmoidal sinus. But in this case, only one polyp was prominent, whereas others may be too small to be visible with rhinoscopy.

### Analysis of the case

#### Miasmatic analysis

The miasmatic analysis was done as per homoeopathic guidelines.<sup>[7]</sup>

#### Psoric symptoms

1. She had a history of small eruption in that nostril.
2. She had a desire for sweet, meat with fat.

#### Sycotic symptoms

1. Pain and bleeding of the right nostril due to polyp.
2. Family history of tuberculosis.
3. Frequent urination.
4. Irritable and revengeful.
5. Coated tongue with a red tip.

#### Syphilitic symptoms

1. Profuse perspiration.

As per the above analysis, the case was mixed miasmatic with sycotic predominance.<sup>[7]</sup>

#### Totality of symptoms

After analysis of the case, the following totality of symptoms was erected.

1. Pain and bleeding per right nostril.

2. Family history of tuberculosis.
3. Desire for sweets, and meat cooked in fat.
4. White-coated tongue with a red tip.
5. Frequent urination.
6. Profuse perspiration.
7. Irritable
8. Revengeful.

### Repertorial totality

Repertorisation of the selected symptoms was done and is shown in the Figure 1.<sup>[8]</sup>

After repertorisation, *Sulphur* and *Acid nitricum* appeared as the first and second choices for the indicated medicine, respectively. To arrive at the similimum, materia medica was referred and the following symptoms and rubrics were found in favour of *Acid nitricum*:

“Irritable, headstrong; hateful and vindictive; inveterate, ill willed, unmoved by apologies”<sup>[9]</sup>

“Affects especially the mucus outlets of the body where skin and mucous membrane join; mouth, nose, rectum, anus, urethra and vagina”<sup>[9]</sup>

“Ulcers: Easily bleeding”<sup>[9]</sup>

“MIND, REVENGEFUL- Calc -c, Lach. Nit-ac. Nux-v”<sup>[10]</sup>

### Therapeutic intervention

Pharmacological intervention was provided through individualised homoeopathy. *Acidum nitricum* 30C was dispensed to the patient on the 1<sup>st</sup> day, with the instruction to take a dose daily, for 4 days.

The medicine was not changed during the course of the treatment, as the patient reported gradual improvement. Placebo was prescribed as per homoeopathic philosophy to cover medicine-free gaps.

The patient was advised to avoid fat, rich and oily food such as meat and fast food as much as possible which might upset the digestion, hampering the action of the medicine. Follow-ups after the first prescription are given in Table 1.

## DISCUSSION

A NP is a common condition that is considered surgical in conventional medicine. However, its presence in childhood is comparatively rare.<sup>[1]</sup> In this case, the homoeopathic medicine helped to resolve the case conservatively, avoiding the need for surgery. In this case, medicine was prescribed based on the individualisation principle of homoeopathy considering general, particular and miasmatic background. This fundamental, time-tested method of prescription was also effective in a study by Banerjee *et al.*<sup>[11]</sup> All the characteristic symptoms were collected in accordance with the aphorism 7 of the *Organon of Medicine*<sup>[12]</sup> and a totality of symptoms was erected. After repertorisation, *Sulphur* and *Acid-nit* emerged as the first and second choices, respectively. Symptoms like the bleeding tendency of the polyp and the revengeful attitude of the patient along with the sycotic nature of the case favoured *Acid-nit*. *Acid-nit* was prescribed in 30C

Remedy Name	Sulph	Nit-ac	Lyc	Calc	Nux-v	Ars	Apis
<b>Totality</b>	16	14	14	14	13	12	11
<b>Symptom Covered</b>	7	7	6	5	5	6	5
[KT] [Mind]Irritability:	3	3	3	3	3	2	3
[KT] [Mind]Malicious:	1	2	2	2	3	2	
[KT] [Mouth]Discoloration.Tongue.Red.Tip:	3	2	2			3	2
[KT] [Stomach]Desires.Fat:	2	3			2	1	
[KT] [Perspiration]Profuse:	2	2	3	3	2	3	1
[KT] [Bladder]Urination.Frequent:	3	1	3	3	3	1	3
[KT] [Nose]Polypus:	2	1	1	3			2

Figure 1: Repertorial sheet.

No. of visit	Date	Symptoms/Outcome	Advice
1	01 November 2021 (First visit)	Polyp in the right nostril with pain and bleeding for 15 days. History of small eruption in the nostril Tongue: Red tip, coated Stool: Regular Sweat: ++ Sleep: Sound	1. <i>Acid nitric</i> 30/Once Daily/4 days 2. Placebo 30/Once Daily/14 days
2	08 November 2021	Swelling persists	1. <i>Acid nitric</i> 30/Once Daily/4 days 2. Placebo 30/Once Daily/14 days
3	22 November 2021	The patient is better, swelling less in size, bleeding occurred only once (the previous day of reporting) in all this while	1. <i>Acid nitric</i> 30/Once Daily/2 days 2. Placebo 30/Once Daily/14 days
4	29 November 2021	The patient is better, size of the swelling in the right-side nostril gradually diminished	1. Placebo 30/Once Daily/14 days.
5	13 December 2021	Size further decreased; bleeding occurred occasionally	1. <i>Acid nitric</i> 30/Once Daily/2 days 2. Placebo 30/Once Daily/14 days
6	27 December 2021	The bleeding stopped, the size of the swelling in the right nostril was <5 mm	1. Placebo 30/Once Daily/14 days
7	03 January 2022	The swelling in the right nostril was significantly reduced, and bleeding did not occur	1. Placebo 30/Once Daily/14 days
8	17 January 2022	NP on the right side, not visible, no bleeding	1. <i>Acid nitric</i> 30/Once Daily/2 days 2. Placebo 30/Once Daily/14 days
9	31 January 2022	Better, NP not visible, no bleeding	1. Placebo 30/Once Daily/14 days.
10	14 February 2022	No visible NP, no bleeding	1. Placebo 30/Once Daily/14 days

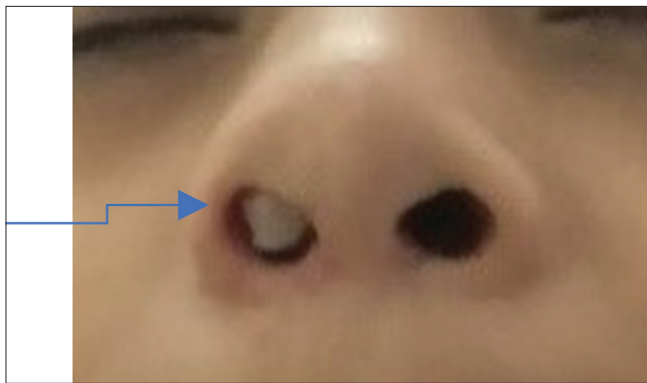
NP: Nasal polyp

potency in four doses. Up to the 2<sup>nd</sup> week, improvement was not observed, however, the author decided to be patient as *Acid-nit* was strongly indicated and also is a well-known anti-sycotic medicine. Thus, the medicine was again repeated in the first follow-up. In the second follow-up, the patient reported gradual improvement and a reduction in the size of the polyp. In subsequent follow-ups, the bleeding stopped and size further diminished, indicating a positive action of the medicine. When improvement starts, ‘wait and watch’ is the best resort. *Acid-nit* and placebo were given from time to time as mentioned in the follow-up Table 1, until complete improvement was achieved. The NPs disappeared and did not reappear even after 10 months. This was confirmed by the photographic evidence taken pre- and post-treatment [Figures 2 and 3]. The Modified Naranjo Score was +9


[Table 2]<sup>[13]</sup> after treatment, which supports the causal attribution between medicine and the changes in the condition of the patient. Such a result has also been found in another study.<sup>[14]</sup> *Acid-nit*, thus, prescribed based on individualisation, saved a child from the painful experience of surgery. In this case, only a few characteristic symptoms could be found in the patient in the short time of busy OPD hours. However, this should not be followed in one’s routine practice. This case report has limitations in the form of limited mental symptoms that could not be elicited from the child due to lack of time, and a non-confirmation of the diagnosis through nasal endoscopy. The given set of symptoms could be a clue for the homoeopathic practitioners about the possibility of picking important symptoms even in the overcrowded OPDs in India. This case presents as a testimony to the positive

**Table 2: Modified Naranjo Criteria**

Domains	Yes	No	Not sure or N/A
1. Was there an improvement in the main symptom or condition for which the homoeopathic medicine was prescribed?	+2 √	-1	0
2. Did the clinical improvement occur within a plausible timeframe relative to the drug intake?	+1 √	-2	0
3. Was there an initial aggravation of symptoms?	+1	0	0 √
4. Did the effect encompass more than the main symptom or condition (i.e., were other symptoms ultimately improved or changed)?	+1 √	0	0
5. Did overall well-being improve? (suggest using a validated scale)	+1 √	0	0
6A Direction of cure: did some symptoms improve in the opposite order of the development of symptoms of the disease?	+1 √	0	0
6B Direction of cure: did at least two of the following aspects apply to the order of improvement of symptoms: – From organs of more importance to those of less importance? – From deeper to more superficial aspects of the individual? – From the top downwards?	+1	0	0
7. Did “old symptoms” (defined as non-seasonal and non-cyclical symptoms that were previously thought to have resolved) reappear temporarily during the course of improvement?	+1	0	0
8. Are there alternate causes (other than the medicine) that—with a high probability— could have caused the improvement? (Consider known course of disease, other forms of treatment and other clinically relevant interventions)	-3	+1 √	0
9. Was the health improvement confirmed by any objective evidence? (e.g., laboratory test and clinical observation, etc.)	+2 √	0	0
10. Did repeat dosing, if conducted, create similar clinical improvement?	+1	0	0 √
Total score: +09			



**Figure 2:** Before treatment



**Figure 3:** After treatment

role of *Acid-nit* prescribed following the individualisation principle in a type of NP.

## CONCLUSION

The successful mitigation of a rare, surgical type of NP with the help of individualised homoeopathy reaffirms our belief that if homoeopathic prescription is utilised carefully and properly, we can treat even surgical cases with this gentle art of healing. A single case is, however, not enough to establish *Acid-nit* as the specific medicine for NPs. Evidence such as case series, randomised control trials are proposed to establish *Acid-nit* as the drug for the treatment of NP, when indicated upon individualisation.

## Acknowledgements

The author is thankful to Dr. Patranu Parui, Junior research fellow, RRI (H), Siliguri for assisting in editing the manuscript.

## Declaration of patient consent

The parent’s consent has been received for publishing the case report for educational purposes, maintaining anonymity.

## Financial support and sponsorship

Nil.

## Conflicts of interest

None declared.

## REFERENCES

1. Di Cicco ME, Bizzoco F, Morelli E, Seccia V, Ragazzo V, Peroni DG, et al. Nasal polyps in children: The early origins of a challenging adulthood condition. *Children (Basel)* 2021;8:997.

2. Kwah JH, Peters AT. Nasal polyps and rhinosinusitis. *Allergy Asthma Proc* 2019;40:380-4.
3. Sudarsan SS, Rajkumar I, Revathi Shree K, Srinivasan K. Is nasal polyp in pediatric cases same as in adult population? *Int J Head Neck Surg* 2021;12:98-100.
4. Boericke W. Boericke's New Manual of Homoeopathic Materia Medica with Repertory. 9<sup>th</sup> ed. New Delhi: B. Jain Publishers (P) Ltd.; 2007.
5. Samiuddin SN, Hulekar S. Nasal obstruction and homoeopathic management. *J Med Pharm Innov* 2021;8:25-8.
6. Rasel NE, Alam MS, Zahan MA, Debnath N, Siddique MM, Hossain MS. Symptomatic assessment of the effectiveness of homeopathic interventions on forty nasal polyp patients: A prospective observational study. *Natl J Integr Res Med* 2020;11:56-60.
7. Speight PA. Comparison of the Chronic Miasms. New Delhi: B. Jain Publishers Pvt. Ltd.; 1998.
8. Kent JT. Repertory of the Homoeopathic Materia Medica. 54<sup>th</sup> Impression, Enriched Indian ed., Reprinted from 6<sup>th</sup> American ed. New Delhi: B. Jain Publishers (P) Ltd.; 2017.
9. Allen HC. Keynotes Rearranged and Classified with Leading Remedies of the Materia Medica and Bowel Nosodes. 10<sup>th</sup> ed. New Delhi: B. Jain Publishers (P) Ltd.; 2005. p. 218.
10. Boger CM. A Synoptic Key to the Materia Medica. New Delhi: B. Jain Publishers (P) Ltd.; 2002. p. 53.
11. Banerjee A, Srivastava BP, Koley M, Saha S. An open-label observational trial to evaluate the possible effects of individualised homoeopathic medicines in symptomatic nasal polyp. *Bengal J Otolaryngol Head Neck Surg* 2019;27:51-9.
12. Hahnemann S. In: Dudgeon RE, Trans. *Organon of Medicine*. 5<sup>th</sup> ed. New Delhi: B. Jain Publishers; 2016.
13. Lamba CD, Gupta VK, van Haselen R, Rutten L, Mahajan N, Molla AM, *et al*. Evaluation of the modified naranjo criteria for assessing causal attribution of clinical outcome to homeopathic intervention as presented in case reports. *Homeopathy* 2020;109:191-7.
14. Jangada S, Banwsal S. Article on nasal polyp in paediatric age group. *J Med Pharm Innov* 2022;9:55-7.

## Un cas de polype nasal pédiatrique, hémorragique, traité avec une homéopathie individualisée : un rapport de cas

**Introduction-** Le polype nasal (NP) est un type de croissance à l'intérieur du nez ou des sinus généralement présent avec la congestion nasale, l'obstruction nasale, et l'anosmie ou l'hyposmie. Il se prête au traitement homéopathique individualisé. Dans ce cas, nous présentons comment un polype nasal chez une femme a été traité avec succès avec une homéopathie individualisée.

**Résumé du cas-** Un cas de polype nasal chez une fille de cinq ans a été présenté au service de consultation externe (OPD) en novembre 2021. Il saignait souvent, surtout quand il était blessé. Il a bloqué la narine droite et était visible de l'extérieur. *Acidum nitricum* (Acid-nit) a été prescrit sur la base de la totalité des symptômes. Après quelques suivis, le patient a commencé à s'améliorer et le saignement a cessé. La taille du polype a également diminué progressivement. Moins d'un mois et demi après le début du traitement, le polype a disparu et le patient n'a plus de polype nasal. Ce cas est le témoignage de l'utilité des polypes nasaux. Des recherches plus approfondies pourraient définir le rôle de l'homéopathie dans la gestion des polypes nasaux.

## Ein pädiatrischer, blutender Nasenpolyp, der mit individueller Homöopathie behandelt wurde: Ein Fallbericht

**Einleitung-** Nasenpolypen (NP) sind Wucherungen in der Nase oder den Nasennebenhöhlen, die typischerweise mit nasaler Verstopfung, nasaler Obstruktion und Anosmie oder Hyposmie einhergehen. Er ist für eine individuelle homöopathische Behandlung gut geeignet. In diesem Fall stellen wir vor, wie ein Nasenpolyp bei einem weiblichen Kind erfolgreich mit individualisierter Homöopathie behandelt wurde. **Zusammenfassung des Falles-** Ein Fall von Nasenpolypen bei einem fünfjährigen weiblichen Kind wurde im November 2021 in der Ambulanz (OPD) vorgestellt. Er blutete häufig, vor allem bei Schmerzen. Er blockierte das rechte Nasenloch und war von außen sichtbar. Aufgrund der Gesamtheit der Symptome wurde *Acidum nitricum* (Acid-nit) verschrieben. Nach einigen Nachuntersuchungen ging es dem Patienten besser und die Blutungen hörten auf. Auch die Größe des Polyps verringerte sich allmählich. Innerhalb von 1 ½ Monaten nach Beginn der Behandlung verschwand der Polyp und die Patientin wurde frei von Nasenpolypen. Dieser Fall ist der Beweis für die Nützlichkeit von Homöopathie bei Nasenpolypen. Weitere Untersuchungen könnten die Rolle der Homöopathie bei der Behandlung von Nasenpolypen definieren.

## बच्ची में नाक के पॉलीप और रक्तस्राव का व्यक्तिगत होम्योपैथी द्वारा इलाज: एक केस रिपोर्ट

**परिचय:** नाक में पॉलीप (एनपी) नाक या साइनस के अंदर होने वाली एक प्रकार की वृद्धि है जिससे आमतौर पर नाक में कॉनजेशन और रुकावट व एनोस्मिया या हाइपोस्मिया होता है। यह व्यक्तिगत होम्योपैथिक उपचार से ठीक हो सकता है। इस मामले में, हमने प्रस्तुत किया है कि कैसे एक बच्ची की नाक में पॉलीप का व्यक्तिगत होम्योपैथी से सफलतापूर्वक इलाज किया गया। **केस सारांश:** नवंबर 2021 में बाह्य रोगी विभाग (ओपीडी) में पांच साल की एक बच्ची के नाक में पॉलीप का मामला प्रस्तुत हुआ। उसमें बार-बार खून बहता था, खासकर चोट लगने पर। इससे दाहिनी नासिका अवरुद्ध थी और यह बाहर से दिखाई दे रहा था, लक्षणों की समग्रता के आधार पर एसिडम नाइट्रिकम (एसिड-नाइट) की सलाह दी गई। कुछ फॉलो-अप के बाद, रोगी में सुधार होने लगा और रक्तस्राव बंद हो गया। पॉलीप का आकार भी धीरे-धीरे कम हो गया। उपचार शुरू करने के 1.5 महीने में रोगी नाक के पॉलीप से मुक्त हो गयी। यह मामला नाक के पॉलीप में होम्योपैथी की उपयोगिता का प्रमाण है। भविष्य के शोध नाक के पॉलीप के प्रबंधन में होम्योपैथी की भूमिका को निश्चित कर सकते हैं।

## Un caso pediátrico de pólipo nasal sangrante tratado con homeopatía individualizada: Informe de un caso

**Introducción-** El pólipo nasal (PN) es un tipo de crecimiento en el interior de la nariz o los senos paranasales que suele cursar con congestión nasal, obstrucción nasal y anosmia o hiposmia. Es susceptible de tratamiento homeopático individualizado. En este caso, presentamos cómo se trató con éxito un pólipo nasal en una niña con homeopatía individualizada. **Resumen del caso:** En noviembre de 2021 se presentó en el Departamento de Pacientes Externos (OPD) un caso de pólipo nasal en una niña de cinco años. Sangraba con frecuencia, especialmente cuando le dolía. Obstruía la fosa nasal derecha y era visible desde el exterior. Se prescribió *Acidum nitricum* (Acid-nit) basándose en la totalidad de los síntomas. Tras algunos seguimientos, el paciente empezó a mejorar y la hemorragia cesó. El tamaño del pólipo también disminuyó gradualmente. Al cabo de un mes y medio de iniciado el tratamiento, el pólipo desapareció y la paciente quedó libre de pólipos nasales. Este caso es el testimonio de la utilidad de los pólipos nasales. Nuevas investigaciones podrían definir el papel de la Homeopatía en el tratamiento de los pólipos nasales.

## 一例儿童出血性鼻息肉，用个体化 势 法治 ：一列病例报告。

**介-** 鼻息肉 (NP) 是鼻子或鼻内的一种生类型，通常表 鼻塞、鼻阻塞、嗅 缺失或嗅 减退。它适用于个体化 势 法治。在这个案例中，我 介 了如何用个体化 势 法成功治 一名女性儿童的鼻息肉。

**病例摘要-** 2021年11月， 部 (OPD) 收到一例五 女童鼻息肉病例。它 常流血，尤其是受 的时候。它堵塞了右鼻孔，从外面可以看到。根据症状的 体情况， 了一种 硝酸 (Acid nit)。 过几次随 ，患者病情 始好 ，出血停止。息肉的大小也逐 小。在 始治 的1个半月内，息肉消失，患者摆脱了鼻息肉。这个病例 明了在鼻息肉中的有效性。 一步的研究可以确定 势 法在鼻息肉治 中的作用。