

28-6-2023

Management of erythrodermic psoriasis with individualised homoeopathy: An evidence-based case report

Dastagiri P

National Homoeopathy Research Institute in Mental Health, Kottayam, Kerala, India, pdastagiri@ccrindia.nic.in

Hafsa Muhammed

National Homoeopathy Research Institute in Mental Health, Kottayam, Kerala, India, muhammadhafsa15@gmail.com

Follow this and additional works at: <https://www.ijrh.org/journal>



Part of the [Alternative and Complementary Medicine Commons](#)

How to cite this article

P D, Muhammed H. Management of erythrodermic psoriasis with individualised homoeopathy: An evidence-based case report. Indian J Res Homoeopathy 2023;17(2):94-102. doi: [10.53945/2320-7094.1235](https://doi.org/10.53945/2320-7094.1235)

This Case Report is brought to you for free and open access by Indian Journal of Research in Homoeopathy. It has been accepted for inclusion in Indian Journal of Research in Homoeopathy by an authorized editor of Indian Journal of Research in Homoeopathy. For more information, please contact ijrhonline@gmail.com.



Management of erythrodermic psoriasis with individualised homoeopathy: An evidence-based case report

Abstract

Introduction: Erythrodermic psoriasis (EP) is a rare and severe variant of psoriasis, with an estimated prevalence among psoriatic patients ranging from 1% to 2.25%. It presents as erythema, oedema, pruritus, ill-defined psoriatic plaques, scaling, hair loss and occasionally exudative lesions and palmoplantar diffuse desquamation with nail changes ranging from mild pitting to severe onychodystrophy, more commonly involving the fingernails than the toenails. **Case Summary:** A 60-year-old male patient, already diagnosed with EP, presented with extensive involvement of body surface area (80–90%). He was treated with Hepar sulphur based on the acute totality, followed by Arsenicum sulphuratum rubrum starting from 30C and then higher potencies as per the requirement and adherence to the homoeopathic principles. At the baseline, the scores of psoriasis area severity index and dermatology life quality index were 54 and 30, respectively and reduced to zero after 8 months of homoeopathic intervention, without any adverse events. Furthermore, during the 2-year follow-up, the patient had two episodes of recurrence of the same complaints with lesser intensity and was treated with the same medicine with favourable results. The causal attribution of changes to homoeopathy was explicitly represented by Modified Naranjo criteria for Homoeopathy and before and after photographs. This evidence based case report may pave the path for further research in treating difficult cases like EP with individualised homoeopathic treatment.

Acknowledgments and Source of Funding

The authors acknowledged Dr K. C. Muraleedharan. Assistant Director (H), Officer In-charge, National Homoeopathy Research Institute in Mental Health, Kottayam, encourages case report writing in scientific publications.

Management of erythrodermic psoriasis with individualised homoeopathy: An evidence-based case report

Dastagiri P*, Hafsa Muhammed

National Homoeopathy Research Institute in Mental Health, Kottayam, Kerala, India

Abstract

Introduction: Erythrodermic psoriasis (EP) is a rare and severe variant of psoriasis, with an estimated prevalence among psoriatic patients ranging from 1% to 2.25%. It presents as erythema, oedema, pruritus, ill-defined psoriatic plaques, scaling, hair loss and occasionally exudative lesions and palmoplantar diffuse desquamation with nail changes ranging from mild pitting to severe onychodystrophy, more commonly involving the fingernails than the toenails. **Case Summary:** A 60-year-old male patient, already diagnosed with EP, presented with extensive involvement of body surface area (80–90%). He was treated with *Hepar sulphur* based on the acute totality, followed by *Arsenicum sulphuratum rubrum* starting from 30C and then higher potencies as per the requirement and adherence to the homoeopathic principles. At the baseline, the scores of psoriasis area severity index and dermatology life quality index were 54 and 30, respectively and reduced to zero after 8 months of homoeopathic intervention, without any adverse events. Furthermore, during the 2-year follow-up, the patient had two episodes of recurrence of the same complaints with lesser intensity and was treated with the same medicine with favourable results. The causal attribution of changes to homoeopathy was explicitly represented by Modified Naranjo criteria for Homoeopathy and before and after photographs. This evidence-based case report may pave the path for further research in treating difficult cases like EP with individualised homoeopathic treatment.

Keywords: Erythrodermic psoriasis, Individualised medicine, Homoeopathy, *Hepar Sulphur*, *Arsenicum sulphuratum rubrum*, Modified Naranjo criteria

INTRODUCTION

Psoriasis is a chronic, non-communicable, disfiguring and disabling disease that has no definitive cure and negatively impacts the patient's quality of life. It occurs at any age but most commonly between 50 and 69. The prevalence ranges between 0.09% and 11.4%, making it a serious global problem. However, in India, the prevalence varies from 0.44% to 2.8%; it is twice more prevalent in males and occurs mainly in the third or fourth decade.^[1,2]

Erythrodermic psoriasis (EP) (ICD 10-L 40) is a rare and severe disease variant among all psoriasis varieties. Its estimated prevalence ranges from 1% to 2.25% among psoriatic patients. Besides, psoriatic erythroderma is the most common cause of erythroderma, leading to 25% of cases.^[3,4] Its aetiology is still unclear, but the evidence is available for a dysregulated immune response occurring in genetically predisposed individuals, following exposure to specific environmental triggers, like infections (streptococcal throat infection),

physical (tattoos, injuries and surgical incisions) and emotional trauma, sunburn, smoking, alcohol, emotional stress. Besides, certain drugs (antidepressants, antihypertensives and anti-cytokine therapies) and rapid withdrawal from the medication have been clinically associated with the initiation, exacerbation and worsening of this disease.^[5]

EP presents with generalised cutaneous lesions such as erythema, oedema, pruritus, ill-defined psoriatic plaques, scaling, hair loss and occasionally exudative lesions and palmoplantar or diffuse desquamation. The fingernails are more commonly involved than the toenails, changes ranging from mild pitting to severe onychodystrophy. Systemic symptoms occur, such as fever, tachycardia, fatigue, malaise, chills,

***Address for correspondence:** Dr. Dastagiri P,
National Homoeopathy Research Institute in Mental Health, Kottayam,
Kerala, India.
E-mail: pdastagiri@ccrh.nic.in

Received: 05 July 2022; **Accepted:** 09 June 2023

Access this article online

Quick Response Code:



Website:
www.ijrh.org

DOI:
10.53945/2320-7094.1235

This is an open access journal, and articles are distributed under the terms of the Creative Commons Attribution-NonCommercial-ShareAlike 4.0 License, which allows others to remix, tweak, and build upon the work non-commercially, as long as appropriate credit is given and the new creations are licensed under the identical terms.

How to cite this article: Dastagiri P, Muhammed H. Management of erythrodermic psoriasis with individualised homoeopathy: An evidence-based case report. Indian J Res Homoeopathy 2023;17:94-102.

dehydration, lymphadenopathy, arthralgia, myalgia, insomnia, sweats, diarrhoea, constipation, weight changes, allodynia and rarely high output heart failure (due to excessive water loss and oedema) leading to death.^[5,6] It is often associated with several complications, including septicaemia, especially staphylococcal infection, with mortality as high as 64%. In addition, fluid and protein losses, electrolyte imbalances and widespread cutaneous vasodilatation can lead to thermoregulation and cardiac failure.^[6]

Conventional medical management addresses the fluid, protein or electrolyte abnormalities, impaired thermoregulation, underlying infections and providing a nutritional diet along with the medications cyclosporine or infliximab, acitretin, methotrexate, steroids, immunosuppressive agents, etanercept, phototherapy and combination therapy.^[3,6-8] The patients pursue other complementary and alternative medicines due to economic factors, dosage regimes and adverse effect profiles of these broader-acting drugs.^[9]

Various published studies have reported evidence for the successful treatment of different types of psoriasis vulgaris with Homoeopathy, without any adverse effects.^[10-15] The present evidence-based case report will add to the evidence in favour of Homoeopathy for the treatment of EP. The case is being reported as per the HOM-CASE guidelines.^[16]

PATIENT INFORMATION

On March 22, 2019, a 60-year-old male, an estate accountant by profession, attended the outpatient department of the National Homoeopathy Research Institute in Mental Health, Kottayam, with severely dry, scaly erythematous eruptions all over the body, severe itching and chills without fever, for 1 week. The itching increased on exposure to cold air and there was burning pain in the skin after scratching.

The complaints started 10 years back with itching on the scalp with silvery scales. The patient took conventional treatment for 3 months and was relieved. After 6 months, similar eruptions appeared over the chin and back region that gradually spread to the whole body, with increased scaling of eruptions. Every year, he had a relapse of the complaints during the winter season and took conventional treatment with some temporary relief. However, the results were not long-lasting, so he finally opted for homoeopathic treatment. He was residing in the Idukki region of Kerala state, which has a cold climate and he abruptly developed itching, burning and redness all over his body, with severe scales and chills after exposure to extreme cold. He confirmed that he had not taken any medication for the last 6 months. No relevant past history was noticed during the case taking. The family history was also not significant.

Psycho-social history

The patient was very anxious and got irritable easily due to his complaints. Because of the disease, he was dissatisfied with his life and was averse to company. Sometimes, he felt

sad and had suicidal thoughts. He had a hasty speech while narrating his complaints.

Physical generals

The patient was fair-skinned and had erythema over the whole body. He had a good appetite and an increased desire for warm drinks, fish, pickles, tea, and fried foods. His bowel habits were regular, and he passed urine without any difficulty. Moreover, he had scanty perspiration and disturbed sleep due to his complaints. He was intolerant to cold air and weather.

Particulars

The skin was red with scales all over the body; the itching aggravated on exposure to cold air and was accompanied by a burning sensation after scratching.

Clinical findings and diagnostic assessment

The patient was afebrile, there was redness with scales all over the body (80–90% body surface area) with onychodystrophy of toenails, pitting and crippling of the fingernails. Other parameters were within the normal limits.

Based on the clinical findings and history, this case diagnosis was confirmed to be acute exacerbation of EP.

Analysis and evaluation of the case

After analysis and evaluation of the symptoms, an acute totality was constructed based on the following symptoms: Irritability, chill, aversion to company, sadness with suicidal disposition, hasty speech, desire for pickles and warm drinks, itching worse on exposure to cold air, burning of the skin after scratching, psoriasis and thermally chilly. Repertorisation was done with Synthesis Treasure edition 2009 v Repertory, Radar Opus 2.2.16, and *Hepar sulphur* (*Hep. sul.*), *Sulphur*, *Sepia*, *Arsenicum album* and *Staphysagria* came up as the leading medicines [Figure 1]. After eliminating *Sulphur* being a hot remedy, we further excluded *Sepia* and *Arsenicum album*, as these did not have peculiar symptoms like weeping tendency or midnight aggravation. *Hep. sul.* was finally selected, conforming to Materia Medica, and covered all the symptoms.^[17]

Therapeutic intervention

The patient was admitted to the institute's in-patient department (IPD) for further management. *Hep. sul.* was selected as the individualised medicine for the patient. The potency and dosage were determined based on the susceptibility as per the patient's age, pathology and the disease's nature. A medium potency of 30 c was thus selected and medicine was administered orally, one dose to be taken every day for 7 days.^[18]

Follow-up and outcome

The second author HM assessed the self-explanatory dermatology life quality index (DLQI).^[19] Questionnaire and the psoriasis area and severity index score (PASI).^[20] The treatment and follow-up details after the acute prescription are given in Table 1.

Chronic Prescription

Sarkar^[21] suggested that after alleviating the acute complaints, one must retake the case when a short-acting remedy has almost relieved the patient; as a corresponding deep-acting or constitutional remedy is often required to complete the cure in treating an acute exacerbation of chronic diseases. Thus, the

chronic symptoms were analysed, evaluated and the totality of symptoms was formed accordingly for repertorisation [Figure 2]. *Arsenic sulphuratum rubrum* was selected as a synthetic remedy for chronic totality. After the administration of this remedy in different potencies and doses over the course of treatment, all his complaints and quality of life improved,

Table 1: Follow-up details of acute prescription

Date	Signs and symptoms	Prescription	PASI and DLQI scores
23 March 2019	Itching, redness, burning sensation, chilliness and scales all over the body. Itching < night. Appetite, Bowel movements-good. No sleep due to itching and burning all over the body [Figure 3]	1. <i>Hep. sul.</i> 30c one dose 2. Placebo, tds	PASI score - 54 DLQI - 30
28 March 2019	Itching all over the body reduces by 60–70%. Redness, chilliness, and Scales were better. Slept well. Figure 4a-c (during acute treatment)	1. <i>Hep. sul.</i> 30c one dose 2. Placebo, tds	-

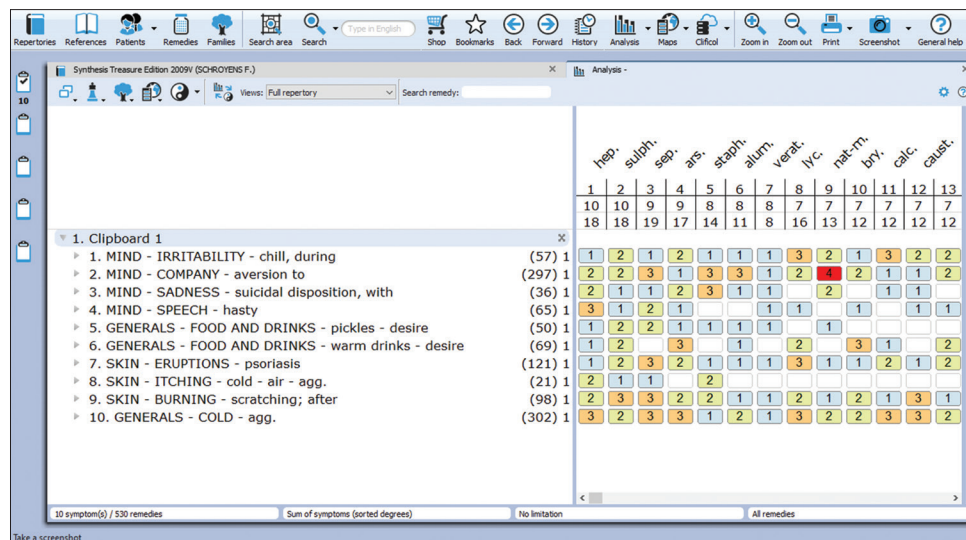


Figure 1: Acute totality repertorisation chart

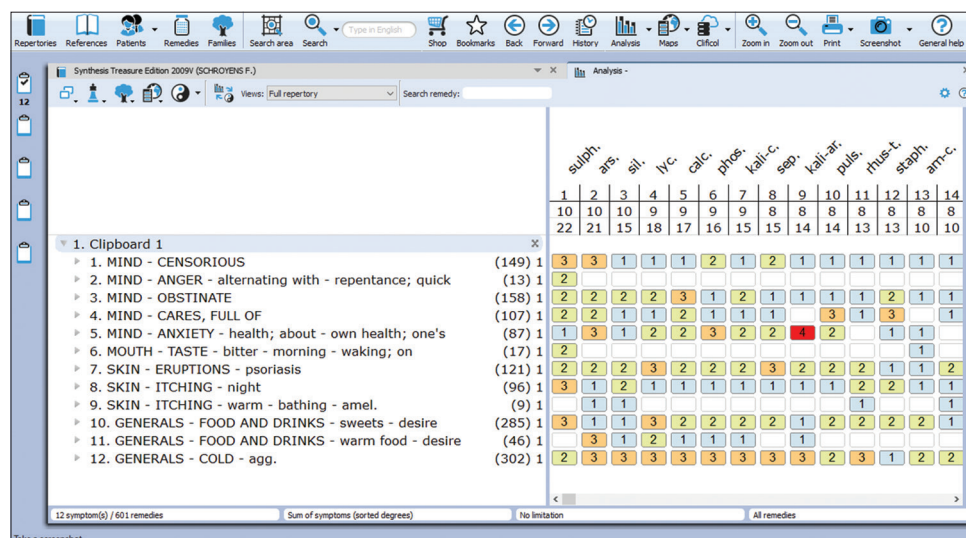


Figure 2: Chronic totality repertorisation chart

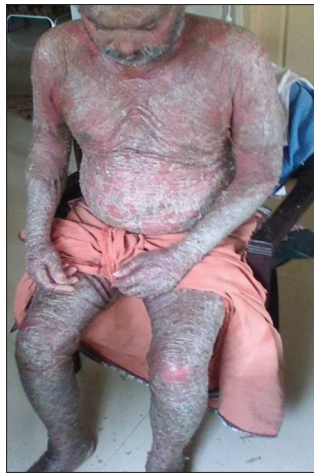

Figure 3: Before the treatment

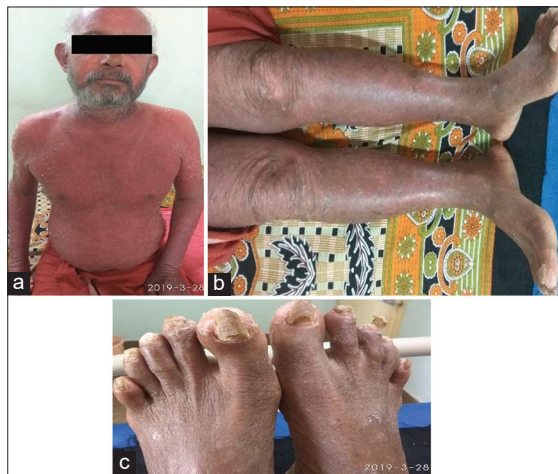

Figure 4: (a-c) During the treatment, after acute prescription

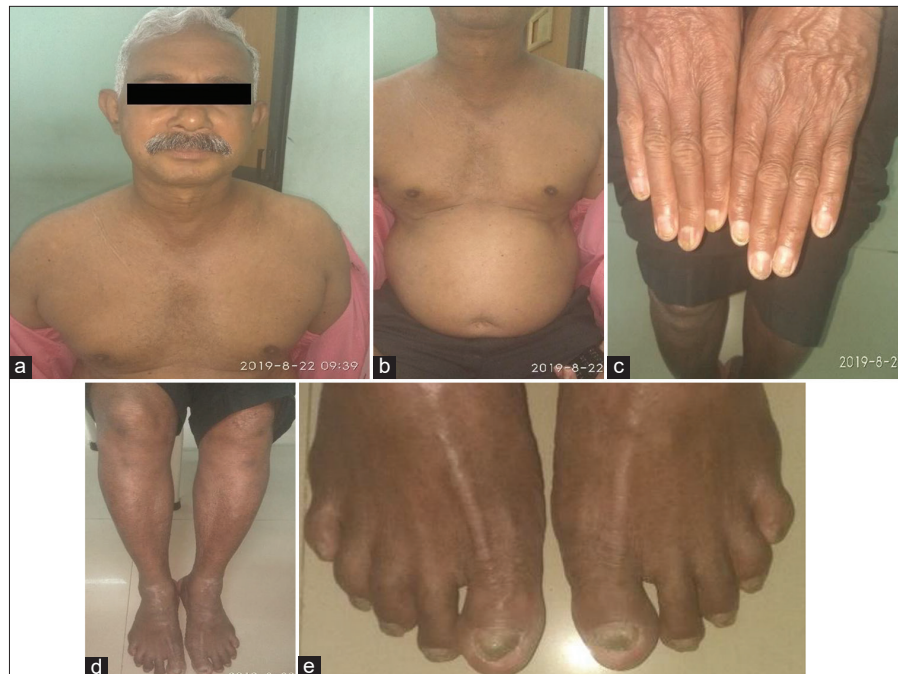

Figure 5: (a-e) During the treatment, after constitutional prescription

with mild recurrence of complaints in between. The follow-up and outcome of DLQI, PASI score and images are mentioned in Table 2.

DISCUSSION

EP is a life-threatening disease that needs emergency intervention. The literature suggests its prevalence is more at 50–69 years. It is primarily seen in men, as in the present case.^[1] Hahnemann explained under §73 that individuals would develop acute disease due to the transient explosion of psora due to exciting causes like excess or an insufficient supply of food, physical impressions, overheating and dissipating strains, physical irritation and mental tension of life.^[22] Furthermore, Kent^[23] and Roberts^[24] also emphasised that the acute exacerbation of the chronic disease is due to latent psoric manifestations, and we should not treat them directly with antipsoric medicines. Therefore, we initially constructed an acute totality based on the presenting complaints, without considering the patient's chronic state, which made it challenging to identify the medicine. Thus, we prescribed *Hep. sul. 30 c* at infrequent intervals and the patient improved symptomatically. At the baseline, the PASI and DLQI scores were 54 and 30, respectively, which denote the highest scores. After the acute condition subsided with *Hep. sul.*, the case was retaken, and a chronic totality was constructed to prescribe a chronic remedy. In § 222, Hahnemann has given instructions that once the acute outbreak has passed, the patient should be given, as soon as possible, an antipsoric treatment, in order to be entirely free from the chronic miasm.^[22] While through repertorisation, *Sulphur*, and *Arsenicum album* came close; *Sulphur* covered the maximum mental and physical generals with the highest grade, and the

Table 2: Follow-up details of constitutional prescription

Date	Signs and symptoms	Prescription	Scores
01 April 2019	Chronic totality	1. <i>Arsenicum sulphuratum rubrum</i> 30C one dose 2. Placebo, tds, 1 day.	PASI Score- 26 DLQI Score-22
12 April 2019	Redness of skin reduced, burning sensation present, sleep disturbed due to itching. The remaining generals are good.	1. <i>Arsenicum sulphuratum rubrum</i> 30C one dose 2. Placebo, tds, 1 day	-
06 May 2019	All complaints were relieved except sleep disturbed due to itching	1. <i>Arsenicum sulphuratum rubrum</i> 200 C two doses, once in 15 days 2. Placebo, tds, 1 month	PASI Score-12. DLQI Score- 11
07 June 2019	Redness of skin, scales, itching decreased and sleep Improved. Crippled toenails better	1. Placebo, 4 doses, weekly once. 2. Placebo, tds, 1 month	PASI Score- 5 DLQI- 5
05 July 2019	No further change in the complaints	1. <i>Arsenicum sulphuratum rubrum</i> 200C two doses, once in 15 days. 2. Placebo, tds, 1 month	PASI Score- 5 DLQI- 5
22 August 2019	Slightly itching increases all over the body at night, Crippled toenails much better Figure 5a-e (during Constitutional treatment)	1. <i>Arsenicum sulphuratum rubrum</i> 200C -2 doses- once in 15 days 2. Placebo, tds, 1 month	PASI Score- 0 DLQI Score-2
22 October 2019	Redness scales decreased, slightly itching < warmth, perspiration, Crippled toenails better Figure 6a-f (after the constitutional treatment)	1. <i>Arsenicum sulphuratum rubrum</i> 200C, 2 doses, once in 15 days 2. Placebo, tds, 1 month	PASI Score- 0 DLQI Score-2
29 November 2019	All complaints are relieved	1. Placebo, 4 doses, once weekly. 2. Placebo, tds, 1 month	PASI Score- 0 DLQI Score-0
03 January 2020	Two psoriatic lesions appear on the back with itching, scales, and mild thickness. All generals were good. No other new complaints.	1. <i>Arsenicum sulphuratum rubrum</i> 1M one dose. 2. Placebo, tds, 1 month	PASI Score- 0.6 DLQI Score-2
04 February 2020	Psoriatic lesions were decreased. Generals were good.	1. Placebo 4 doses, once weekly. 2. Placebo, tds, 1 month	PASI Score- 0 DLQI Score-0

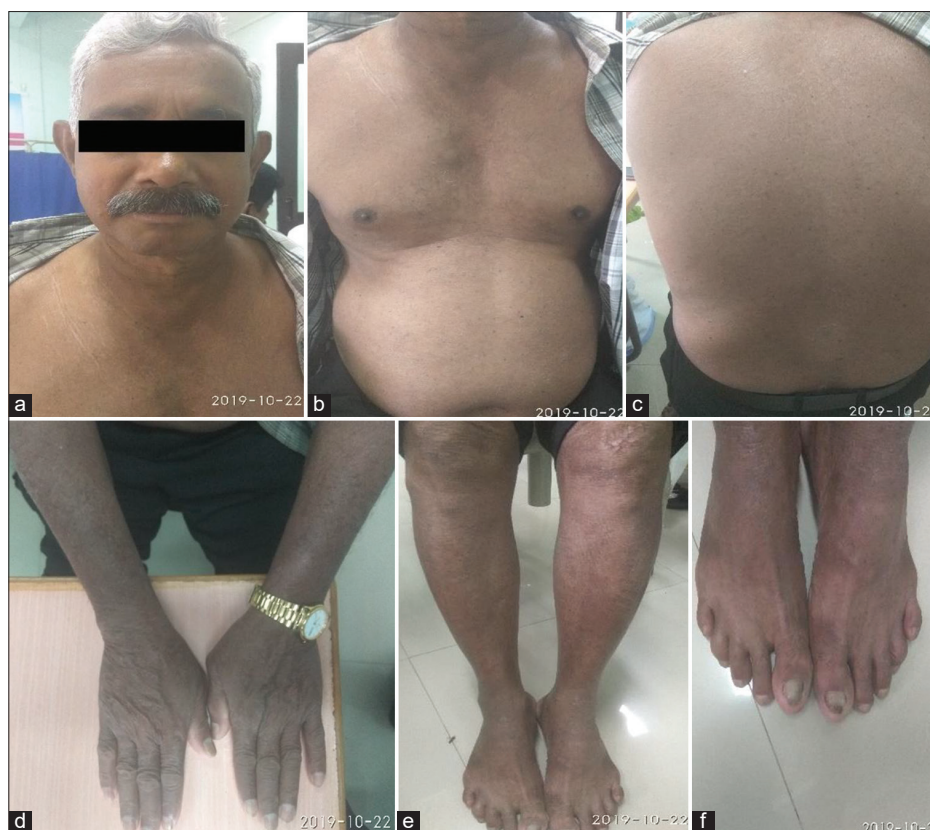
**Figure 6:** (a-f) After the constitutional prescription

Table 3: Modified Naranjo Criteria for Homoeopathy Score

Domains	Yes	No	Not sure or N/A	Justification
Was there an improvement in the main symptom or condition for which the homoeopathic medicine was prescribed?	+2	-1	0	The patient came with severe itching, redness and exfoliation of skin all over the body. After the intervention, the main complaints improved significantly
Did the clinical improvement occur within a plausible Time frame relative to the medicine intake?	+1	-2	0	The patient had an acute exacerbation of chronic complaints with the intervention and marked improvement
Was there a homoeopathic aggravation of symptoms?	+1	0	0	Not observed
Did the effect encompass more than the main symptom or condition (i.e., were other symptoms, not related to the main presenting complaint, improved or changed)?	+1	0	0	His sleep and quality of life were improved
Did overall well-being improve? (suggest using a validated scale or mention about changes in physical, emotional and behavioural elements)	+1	0	0	Significant improvement was observed in the PASI and DLQI score before and after the intervention
Direction of cure: Did some symptoms improve in the opposite order of the development of symptoms of the disease?	+1	0	0	Not observed
Direction of cure: Did at least one of the following aspects apply to the order of improvement in symptoms	+1	0	0	Not observed
- From organs of more importance to those of less importance?				
- From deeper to more superficial aspects of the individual?				
- From the top downwards?				
Did 'old symptoms' (defined as non-seasonal and noncyclical symptoms that were previously thought to have resolved) reappear temporarily during the course of improvement?	+1	0	0	Not observed
Are there alternative causes (i.e. other than the medicine) that – with a high probability –could have produced the improvement? (consider the known course of the disease, other forms of treatment, and other clinically relevant interventions)	-3	+1	0	The patient had stopped entirely other modes of treatment. So, we do not see any other alternate cause that could produce such marked improvement
Was the health improvement confirmed by any objective evidence? (e.g., investigations, clinical examination, etc.)	+2	0	0	Before and after photographs
Did repeat dosing, if conducted, create similar clinical improvement?	+1	0	0	Yes
Total score: +9				

N/A: Not applicable, The selected score is in bold font.

patient was chilly. Upon further enquiry, we could not find the characteristic symptoms of *Arsenicum album*. Hence, we considered prescribing a medicine having components of both,^[25] already one of the prescribing principles, with positive results. Thus, we prescribed *Arsenicum sulphuratum rubrum* 30C initially, followed by 200C and 1M, at infrequent intervals. We treated this case for 1 month in IPD with individualised homoeopathic intervention. The patient was on a regular diet as per IPD norms. Then, after his complaints were relieved, as reflected through the PASI and DLQI scores, the patient was discharged and was followed up in the in the out-patient department.

During the follow-up, all his complaints progressively decreased without any aggravation, which entitles Kent's^[23] fourth observation like '*no aggravation with the recovery of the patient,*' which specifies the correct remedy and potency. The literature suggests that this illness has a recurrence, and in 2 years of follow-up, he had had two episodes with lesser intensity, and the same medicine was repeated based on the

intensity of the signs and symptoms. Besides these, as literature designates,^[5-7] onychodystrophy is primarily seen in fingernails rather than toenails; in contrast, in this patient, toenails were severely affected, recovered and restored to a healthy state, which is not frequently observed. As a result, both PASI and DLQI scores were reduced to zero within 8 months of intervention.

The Modified Naranjo Criteria for Homeopathy (MONARCH)^[26] was used for causality assessment, and the score of +9, showed that homoeopathic medication could be the reason behind the improvement in the case [Table 3].

The limitation of the case remains that the longer follow-up could not be carried out, despite the efforts to contact the patient. Further, the recurrence of lesions in January could be followed only for a month during which they were reported to be better. However, in the best case scenario, it is recommended that such recurrences are followed up for a longer duration.

CONCLUSION

This evidence-based case report illustrates that individualised homoeopathic treatment, based on the totality of symptoms, could effectively treat EP, thus, paving the path for further research to evaluate the efficacy of Homoeopathy in treating life-threatening diseases like EP without any adverse events.

ACKNOWLEDGEMENT

The authors acknowledge Dr. K. C. Muraleedharan, Assistant Director (H), Officer In-charge, National Homoeopathy Research Institute in Mental Health, Kottayam, for encouraging case report writing in scientific publications.

Declaration of the patient's consent

The authors certify that they have obtained patient's consent and that the patient has given consent for his photographs and other clinical information to be reported in the journal. In addition, the patient was made to understand that his name and initials would not be published and efforts would be made to conceal his identity.

Financial support and sponsorship

Nil.

Conflicts of interest

None declared.

REFERENCES

- World Health Organization. Global Reports on Psoriasis. Geneva: World Health Organization; 2016. Available from: https://apps.who.int/iris/bitstream/handle/10665/204417/9789241565189_eng.pdf?sequence=1 [Last accessed on 2022 Nov 16].
- Dogra S, Yadav S. Psoriasis in India: Prevalence and pattern. *Indian J Dermatol Venereol Leprol* 2010;76:595-601.
- Singh RK, Lee KM, Ucmak D, Brodsky M, Atanelov Z, Farahnik B, *et al.* Erythrodermic psoriasis: Pathophysiology and current treatment perspectives. *Psoriasis (Auckl)* 2016;6:93-104.
- Panda M, Raj C, Panda AK, Debata I. Secukinumab in erythrodermic psoriasis: Real world experience of 6 patients successfully treated by injecting at unconventional sites. *Indian J Dermatol* 2021;66:677-80.
- Di Meglio P, Villanova F, Nestle FO. Psoriasis. *Cold Spring Harb Perspect Med* 2014;4:a015354.
- Heinrich M, Cook E, Roach J, Juarez RM, Payne D, Atkins R, *et al.* Erythrodermic psoriasis secondary to systemic corticosteroids. *Proc (Bayl Univ Med Cent)* 2019;33:113-4.
- Lo Y, Tsai TF. Updates on the treatment of erythrodermic psoriasis. *Psoriasis (Auckl)* 2021;11:59-73.
- Rendon A, Schakel K. Psoriasis pathogenesis and treatment. *Int J Mol Sci* 2019;20:1475.
- Bagmar K, Kundu T, Ahiwale M, Nimbhore G, Thakre T, Kadam K, *et al.* Study of efficacy of homoeopathic medicines in management of psoriasis cases treated after 2018: A retrospective study. *J Homoeopathy* 2022;4:37-46.
- Witt CM, Ludtke R, Willich SN. Homeopathic treatment of patients with Psoriasis--a prospective observational study with 2 years follow-up. *J Eur Acad Dermatol Venereol* 2009;23:538-43.
- Rahman S, Dey JK. A case report of plantar Psoriasis treated with homoeopathy. *Homoeopathic Links* 2018;31:248-53.
- Mandal S, Biswas B. An evidence based case of planter psoriasis treated by individualized homoeopathic medicine. *Int J Ayush Case Rep* 2021;5:84-90.
- Nwabudike LC. Psoriasis and homeopathy. *Proc Rom Acad Ser* 2011;3:237-42.
- Divya T, Sadhukhan M, Rath P, Sarangi MR, Mittal R, Prusty AK, *et al.* Open-label study to evaluate the response to homeopathic treatment of psoriasis. *OBM Integr Complement Med* 2022;7:1-21.
- Mahesh S, Shah V, Mallappa M, Vithoulkas G. Psoriasis cases of same diagnosis but different phenotypes-Management through individualized homeopathic therapy. *Clin Case Rep* 2019;7:1499-507.
- Van Haselen RA. Homeopathic clinical case reports: Development of a supplement (HOM-CASE) to the CARE clinical case reporting guideline. *Complement Ther Med* 2016;25:78-85.
- Boericke W. Boericke's New Manual of Homoeopathic Treatment with Repertory. 3rd ed. New Delhi: B. Jain Publishers (P) Ltd.; 2010. p. 78-9, 287-9.
- Close S. In: Homoeopathic Posology. The Genius of Homoeopathy, Lecture, and Essays on Homoeopathic Philosophy. Ch. 13. New Delhi: B. Jain Publishers Pvt. Ltd.; 2001. p. 183-212.
- Finlay AY, Khan GK. Dermatology Life Quality Index (DLQI)--a simple, practical measure for routine clinical use. *Clin Exp Dermatol* 1994;19:210-6.
- Mattei PL, Corey KC, Kimball AB. Psoriasis Area Severity Index (PASI) and the Dermatology Life Quality Index (DLQI): The correlation between disease severity and psychological burden in patients treated with biological therapies. *J Eur Acad Dermatol Venereol* 2014;28:333-7.
- Sarkar B.K. The clinical varieties of Acute diseases. In: Hahnemann's Organon of Medicine. 9th ed. New Delhi: Birla Publications; 2004. p. 343-4.
- Hahnemann S, Boericke W. Organon of Medicine. 6th ed. New Delhi: B. Jain Publishers Pvt. Ltd.; 1996. p. 160-1.
- Kent JT. Lectures on Homoeopathic Philosophy Reprint. New Delhi: B. Jain Publishers Pvt. Ltd.; 1999. p. 174-8, 224-34.
- Roberts HA. The Principles and Art of Cure by Homoeopathy. Ch. 8. New Delhi: B. Jain Publishers Pvt. Ltd.; 1999. p. 78-9.
- Dastagiri P, Savera KK. Lichen spinulosus: Successfully treated with individualised homoeopathic treatment-a case report. *Homoeopathic Links* 2022;35:302-6.
- Lamba CD, Gupta VK, van Haselen R, Rutten L, Mahajan N, Molla AM, *et al.* Evaluation of the modified naranjo criteria for assessing causal attribution of clinical outcome to homeopathic intervention as presented in case reports. *Homeopathy* 2020;109:191-7.

Traitement homéopathique individualiste du psoriasis érythrodermique - Rapport de cas basée sur des preuves.

L'Introduction: Le psoriasis érythrodermique (PE) est une variante rare et grave du psoriasis, avec une prévalence estimée chez les patients psoriasiques allant de 1 % à 2,25 %. Il se présente sous forme d'érythème, oedème, prurit, plaques psoriasiques mal définies, desquamation diffuse palmoplantaire, perte de cheveux, et parfois des lésions exsudatives et desquamation diffuse avec des changements d'ongles allant de piqures légères à onychodystrophie sévère, plus souvent les ongles des doigts que les ongles des orteils.

Résumé de cas: Un homme de 60 ans, ayant reçu un diagnostic antérieur de SE, présentait une atteinte importante de la surface corporelle (80-90 %). Il a été traité avec *Hepar Sulphur* sur la base de la totalité aiguë suivie par *Arsenicum Sulphuratum rubrum* à partir de 30c puis des puissances plus élevées selon l'exigence et le respect des principes. Au départ, l'indice de gravité de la région du psoriasis (ISDP) et l'indice de dermatologie de la qualité de vie (QLD) affichaient respectivement 54 et 30 et étaient réduits à zéro après huit mois d'intervention homéopathique, sans effets indésirables. De plus, au cours des deux années de suivi, il a eu deux épisodes de récurrence des mêmes troubles avec moins d'intensité et a été traité avec le même médicament avec des résultats favorables. L'attribution causale des changements a été explicitement représentée par les critères de Naranjo modifié pour l'homéopathie, et avant et après les photographies. Ce rapport de cas fondé sur des données probantes pourrait ouvrir la voie à d'autres recherches sur le traitement de cas difficiles comme l'PE par un traitement homéopathique individualisé.

Individualistische homöopathische Behandlung der erythrodermischen Psoriasis - ein evidenzbasierter Fallbericht

Einleitung: Die erythrodermische Psoriasis (EP) ist eine seltene und schwere Variante der Psoriasis mit einer geschätzten Prävalenz unter Psoriatikern von 1% bis 2,25%. Sie äußert sich in Form von Erythemen, Ödemen, Juckreiz, unscharfen psoriatischen Plaques, Schuppung, Haarausfall und gelegentlich exsudativen Läsionen und diffuser palmoplantarer Schuppung mit Nagelveränderungen, die von leichter Lochfraßbildung bis zu schwerer Onychodystrophie reichen und häufiger die Fingernägel als die Zehennägel betreffen.

Zusammenfassung des Falles: Ein 60-jähriger Patient, bei dem zuvor EP diagnostiziert worden war, stellte sich mit einer großflächigen Beteiligung der Körperoberfläche (80-90 %) vor. Er wurde mit *Hepar Sulphur* auf der Grundlage der akuten Gesamtheit behandelt, gefolgt von *Arsenicum Sulphuratum rubrum*, beginnend mit 30c und dann in höheren Potenzen, je nach Bedarf und Einhaltung der Grundsätze. Zu Beginn der Behandlung betrugen der Psoriasis Area Severity Index (PASI) und der Dermatology Life Quality Index (DLQI) 54 bzw. 30 und sanken nach acht Monaten homöopathischer Behandlung auf Null, ohne dass es zu unerwünschten Ereignissen kam. Während der zweijährigen Nachbeobachtungszeit traten die gleichen Beschwerden in zwei Fällen mit geringerer Intensität erneut auf und wurden mit demselben Arzneimittel behandelt, was zu einem günstigen Ergebnis führte. Die kausale Zuordnung der Veränderungen wurde anhand der modifizierten Naranjo-Kriterien für Homöopathie sowie anhand von Vorher-Nachher-Fotos explizit dargestellt. Dieser evidenzbasierte Fallbericht kann den Weg für weitere Forschungen zur Behandlung schwieriger Fälle wie EP mit einer individualisierten homöopathischen Behandlung ebnen.

एरिथ्रोडर्मिक सोरायसिस का व्यक्तिगत होम्योपैथिक उपचार - एक साक्ष्य - आधारित केस रिपोर्ट

परिचय: एरिथ्रोडर्मिक सोरायसिस (EP) एक प्रकार का दुर्लभ और गंभीर सोरायसिस (छालरोग) होता है, जिसका सोरायटिक रोगियों में अनुमानित प्रसार 1% से 2.25% तक है। यह रोग एरिथेमा, सूजन, खुजली अस्पष्ट सोरियाटिक प्लेक, स्केलिंग, बालों का झड़ना और कभी-कभी स्त्रावी (एक्सयूडेटिव) घावों और पामोप्लांटर डिक्लेमेशन के साथ में पाया जाता है, जिसके कारण नाखून में हल्के पिटिंग से लेकर गंभीर ओनिकोडिस्ट्रोफी तक के परिवर्तन जो आमतौर पर हाथों के नाखूनों की तुलना में पैरों के नाखूनों में ज्यादा होते हैं इन लक्षणों से प्रस्तुत होता है।

केस का सारांश: एक 60 वर्षीय पुरुष रोगी का शरीर विस्तृत सतह क्षेत्र (80-90%) रोग से त्रस्त था, और उनमें पहले EP रोग निदान हुआ था। अका उपचार एक्यूट टोटैलिटी के आधार पर *हेपर सल्फर* और बाद में *आर्सेनिकम सल्फ्यूरैटम रुब्रम* से उनका उपचार से शुरू करते हुए और फिर उच्च पोटेंसी आवश्यकता और सिद्धांतों का पालन करते हुए किया गया। प्रारंभ में, सोरायसिस एरिया सेविअरीटी इंडेक्स (PASI) और डर्मेटोलॉजी लाइफ क्वालिटी इंडेक्स (DLQI), स्कोर क्रमशः 54 और 30 थे और वे बिना किसी दुष्प्रभाव के होम्योपैथिक हस्तक्षेप के आठ महीने बाद ठीक हो गए। फिर दो साल के उपचार के दौरान, उन्हें पहले से कम गंभीर ऐसे ही लक्षण दो बार हुए और उसी दवा के साथ उपचार किया गया और इसके अनुकूल परिणाम मिले। होम्योपैथी के लिए संशोधित नारन्जो मानदंडों, और पहले की तस्वीरों और बाद में दिखे परिवर्तन स्पष्ट रूप से प्रस्तुत हुए। यह साक्ष्य-आधारित केस रिपोर्ट व्यक्तिगत होम्योपैथिक उपचार के माध्यम से EP जैसे जटिल मामलों के इलाज में, भविष्य में होने वाले शोध के लिए रास्ते खोल सकती है।

Manejo homeopático individualista de la psoriasis eritrodérmica: Un informe de caso basado en la evidencia

Introducción: La psoriasis eritrodérmica (EP) es una variante rara y grave de la psoriasis, con una prevalencia estimada entre los pacientes psoriásicos que oscila entre el 1% y el 2,25%. Se presenta como eritema, edema, prurito, placas psoriásicas mal definidas, descamación, pérdida de cabello y, ocasionalmente, lesiones exudativas y descamación difusa palmoplantar con cambios en las uñas que van desde picaduras leves hasta onicodistrofia severa, que afecta más comúnmente las uñas de las manos que las uñas de los pies.

Resumen del caso: El paciente varón de 60 años, diagnosticado previamente de EP, con afectación extensa del área de superficie corporal (80-90%). Fue tratado con *Hepar Sulphur* basado en la totalidad aguda seguida de *Arsenicum Sulphuratum rubrum* a partir de 30c y luego potencias más altas según el requisito y la adhesión a los principios. Al inicio del estudio, las puntuaciones del Índice de gravedad del área de psoriasis (PASI) y del Índice de calidad de vida en dermatología (DLQI) fueron 54 y 30 respectivamente, y se redujeron a cero después de ocho meses de intervención homeopática, sin ningún evento adverso. Además, durante los dos años de seguimiento, tuvo dos episodios de recurrencia de las mismas molestias con menor intensidad y fue tratado con el mismo medicamento con resultados favorables. La atribución causal de los cambios fue explícitamente representada por los criterios modificados de Naranjo para la homeopatía, y antes y después de las fotografías. Este informe de caso basado en la evidencia puede allanar el camino para futuras investigaciones en el tratamiento de casos difíciles como la EP con tratamiento homeopático individualizado.

皮病性 屑病的个体化 势 法治 : 一 例循 病例报告.

介: 皮病性 屑病 (EP) 是一种罕 且 重的 屑病 体, 在 屑病患者中的患病率估 在1%至2.25%之 。它 表 斑、水 、瘙 痒、定义不清的 屑病斑块、脱屑、脱 , 偶尔出 渗出性病 和掌跖弥漫性脱屑, 指甲 化 范 从 度点 到 重的甲 不良, 更常 的是涉及指甲而不是脚趾甲。

病例 : 一名60 男性患者, 先前 断 EP, 表 体表面 广泛受累 (80-90%)。他接受了基于急性全量的肝 素硫(Hepar Sulphur)治 , 然后从30 氏度 始接受 色硫化砷(Arsenicum Sulphuratum rubrum)治 , 然后根据 要求和原 行更高的治 。在基 时, 屑病区域 重程度指数 (PASI) 和皮肤病学生活 量指数 (DLQI) 得分 分别 54和30, 在 势 法干 8个月后降至零, 没有任何不良事件。此外, 在两年的随 中, 他有两次复 , 症状 强度 小, 并接受了相同 物的治 , 果良好。 化的因果归因由 势 法的改良Naranjo 准以及前后照片明确 表示。这份循 病例报告可能 一步研究用个性化 势 法治 EP等疑 病例 平道路。