

24-3-2023

## Obviating surgical amputation of diabetic gangrene through homoeopathy – A case report

Poojitha Ankerela

*Department of Repertory, A.M. Shaikh Homoeopathic Medical College and PG Research Centre, Belagavi, Karnataka, India,*  
dr.poojitha.ankerla@gmail.com

Sangeeta Belgavimath

*Department of Repertory, A.M. Shaikh Homoeopathic Medical College and PG Research Centre, Belagavi, Karnataka, India,*  
drsangeetabelgavimath@ymail.com

Premalata Rotti

*Department of Repertory, A.M. Shaikh Homoeopathic Medical College and PG Research Centre, Belagavi, Karnataka, India,*  
drpremlatarotti@yahoo.in

Follow this and additional works at: <https://www.ijrh.org/journal>

 Part of the [Homeopathy Commons](#)

---

### How to cite this article

Ankerela P, Belgavimath S, Rotti P. Obviating surgical amputation of diabetic gangrene through homoeopathy – A case report. Indian J Res Homoeopathy 2023;17(1). doi: [10.53945/2320-7094.1163](https://doi.org/10.53945/2320-7094.1163)

This Case Report is brought to you for free and open access by Indian Journal of Research in Homoeopathy. It has been accepted for inclusion in Indian Journal of Research in Homoeopathy by an authorized editor of Indian Journal of Research in Homoeopathy. For more information, please contact [ijrhonline@gmail.com](mailto:ijrhonline@gmail.com).



---

## Obviating surgical amputation of diabetic gangrene through homoeopathy – A case report

### Abstract

**Introduction:** Gangrene is defined as the decay or death of an organ or tissue due to a compromised blood supply. It is a perilous and fatal condition occurring most commonly due to diabetes. In general, people with diabetes have a significantly increased risk of lower extremity gangrene leading to amputation.

**Case Summary:** A 70-year-old woman presented with diabetic gangrene of her right leg and foot since 4 months. The patient complained of swelling and blackish discoloration of the right foot and leg with offensive discharging ulcers on the first and third toes. She was diagnosed with diabetic foot gangrene and advised to undergo surgical amputation of the foot and debridement of the leg by a local surgeon within 4–5 days to stop the spread of gangrene. After an unsatisfactory outcome, the patient turned to homoeopathy to avoid amputation. After a detailed case-taking, analysis and repertorisation, Arsenic album 30C was prescribed. Within 3–4 months, there was an improvement in the limb without any surgical intervention. Calendula officinalis Q was used for cleaning the wound and regular dressing. This case depicts the importance of individualised homoeopathic medicine in treating gangrene effectively, thus obviating amputation.

### Acknowledgments and Source of Funding

-

# Obviating surgical amputation of diabetic gangrene through homoeopathy – A case report

Poojitha Ankerela\*, Sangeeta Belgavimath, Premalata Rotti

Department of Repertory, A.M. Shaikh Homoeopathic Medical College and PG Research Centre, Belagavi, Karnataka, India

## Abstract

**Introduction:** Gangrene is defined as the decay or death of an organ or tissue due to a compromised blood supply. It is a perilous and fatal condition occurring most commonly due to diabetes. In general, people with diabetes have a significantly increased risk of lower extremity gangrene leading to amputation. **Case Summary:** A 70-year-old woman presented with diabetic gangrene of her right leg and foot since 4 months. The patient complained of swelling and blackish discoloration of the right foot and leg with offensive discharging ulcers on the first and third toes. She was diagnosed with diabetic foot gangrene and advised to undergo surgical amputation of the foot and debridement of the leg by a local surgeon within 4–5 days to stop the spread of gangrene. After an unsatisfactory outcome, the patient turned to homoeopathy to avoid amputation. After a detailed case-taking, analysis and repertorisation, *Arsenic album* 30C was prescribed. Within 3–4 months, there was an improvement in the limb without any surgical intervention. *Calendula officinalis* Q was used for cleaning the wound and regular dressing. This case depicts the importance of individualised homoeopathic medicine in treating gangrene effectively, thus obviating amputation.

**Keywords:** Amputation, *Arsenic album*, Fasting blood sugar, Gangrene, Homoeopathy, Post prandial blood sugar

## INTRODUCTION

Gangrene is the localised death of tissue, caused by inadequate blood supply, which may result from injury, infection and diabetes mellitus. Diabetics possess three distinct factors, which make their limbs liable to gangrene formation. First, sugar-laden tissues lower their resistance to infection. The second factor is a liability to the formation of atheroma in the arteries. In the lower limb, the arterial occlusive disease involves the popliteal artery and its branches down to the pedal arches. The third factor is diabetic neuropathy, which impairs sensation and lower limbs get more prone to injuries and infections.<sup>[1,2]</sup> As a result of this, the pressure areas of the foot become complicated by trophic ulcers.

Both dry and wet gangrene are seen in diabetics. In dry gangrene, there is a classic line of demarcation between the necrotic and normal tissue with little or no discharge. Infection plays a major role in wet gangrene, which spreads rapidly and is often lethal. In wet gangrene, trophic ulcers are seen at the pressure sites usually at the metatarsal heads, particularly over the first or third metatarsal head.<sup>[1]</sup>

According to the International Diabetes Federation, in 2015, approximately 415 million people were suffering from diabetes

worldwide, and this number is expected to reach 640 million by the year 2040.<sup>[3]</sup> Globally, 1 million amputations occur every year; approximately one amputation every 30 s. It is estimated that the total number of amputees will reach 435 million by 2030; of these, over 54% will be affected only by peripheral vascular diseases, especially diabetes mellitus. Moreover, the mortalities among people who undergo amputation are very high.<sup>[4]</sup> In India, 69.2 million people are affected with diabetes, showing an overall prevalence of 9.3% with the loss of a lower extremity. A community-based study states for every 20 people, a lower limb is lost due to diabetes and around 45,000 lower limbs are amputated each year.<sup>[5]</sup>

Homoeopathic literature provides a good scope for treating cases of gangrene and preventing surgical amputation.<sup>[4,6,7]</sup> Here, we present a case of diabetic wet gangrene, treated with an individualised homoeopathic approach. *Calendula officinalis*

**\*Address for correspondence:** Poojitha Ankerela, Department of Repertory, A.M. Shaikh Homoeopathic Medical College and PG Research Centre, Belagavi, Karnataka, India.  
E-mail: dr.poojitha.ankerla@gmail.com

**Received:** 05 March 2022; **Accepted:** 8 March 2023

### Access this article online

#### Quick Response Code:

Available in print version only

**Website:**  
www.ijrh.org

**DOI:**  
10.53945/2320-7094.1163

This is an open access journal, and articles are distributed under the terms of the Creative Commons Attribution-NonCommercial-ShareAlike 4.0 License, which allows others to remix, tweak, and build upon the work non-commercially, as long as appropriate credit is given and the new creations are licensed under the identical terms.

**How to cite this article:** Ankerela P, Belgavimath S, Rotti P. Obviating surgical amputation of diabetic gangrene through homoeopathy – A case report. *Indian J Res Homoeopathy* 2023;17(1):39-45.

Q was used for cleaning the wound and regular dressing was done. No antiseptics or external applications (ointments) were used for dressing. This report adds to the existing evidence of homoeopathic management of diabetic gangrene.

## CASE REPORT

### Patient history

A 70-year-old woman presented with diabetic gangrene of the right leg and foot since 4 months. She was a known case of diabetes since 20 years and was on oral hypoglycaemic medicines. The patient complained of swelling and blackish discoloration of the right foot and leg with an ulcer on the first and third toes. Complaints had started with an ulcer over the big toe, and gradually, it had spread upwards with swelling and blackish discoloration of the right foot and leg. The condition progressively deteriorated over a month with reduced vascularity and blister over the medial aspect of the right lower leg. She was advised to undergo surgical amputation of the foot and debridement of the leg by a local surgeon within 4–5 days to stop the spread of gangrene. There was a putrid, watery, offensive discharge from the ulcer and a burning sensation (as of hot coals) in the foot and leg, especially the big toe, which was worse during the night.

### Past history

She had a history of similar complaints in the left foot 3 years back, for which the patient underwent surgical debridement of the foot and big toe amputation.

### Physical generals

Her appetite was more than usual, and she had a desire for sweets and meat. She had an extreme thirst for water at frequent intervals and was chilly. She could not tolerate cold air/cold weather. Her bowels were regular and satisfactory. She had an increased frequency of micturition, which could also be a result of raised blood glucose. Her sleep was disturbed at night due to her present complaints.

### Mental generals

Mentally, the patient was restless, could not sit in one place for a long time and changed places or walk around to stay calm. She had a feeling that she was left alone, and no one was there to look after her. She had expressed that it was better to die than live with this disease, as there was no relief even after taking treatment at different hospitals.

### Clinical findings

On inspection, the skin appeared black, thin and shiny with a loss of hair and there was no clear line of demarcation. Circular, punched-out ulcers of the big and third toes, with a blister on the lower medial aspect of the right leg and offensive discharge were noted [Figure 1]. The left big toe was not there due to prior amputation, and no other abnormal signs were noted in the left lower limb.

On palpation, swelling of the right leg and foot with pitting oedema was noted. The ulcer was located on the ventral

aspect of the first and third toes, extending deep up to the muscles, with a punched-out edge, floor was exudated with purulent discharge, base indurated, fixed and non-tender. The surrounding skin of the ulcer was callous-like and thickened. The posterior tibial and dorsalis pedis pulses were not palpable.

### Diagnostic assessment

Her laboratory investigations revealed high blood glucose parameters: Fasting blood sugar was 181 mg/dL and post-prandial blood sugar was 272 mg/dL, glycosylated haemoglobin was 9.2% on July 09, 2021 and above-mentioned clinical findings which were suggestive of diabetic wet gangrene with a trophic ulcer.

### Totality of Symptoms

The totality included the following symptoms:

- Despair of recovery
- Restlessness drives her from place to place.
- Feels that she is left alone.
- Swelling and blackish discoloration of foot and leg
- Watery, offensive discharge from the ulcer
- Sensation of burning from coals more during the night, in sleep
- Modalities: worse at night, from getting feet wet
- Desires: sweets, meat (moderate intensity)
- Chilly patient.

### Selection of remedy

This case was repertorised by Hompath classic M.D version 8 software using complete repertory.<sup>[8]</sup> Considering the reportorial result [Figure 2] and referring to materia medica, *Arsenic album* was selected as similimum.

### Prescription and follow-up

On the day of the visit, *Arsenic album* 30C was prescribed, to be taken thrice daily for 2 days and followed by a placebo for 4 months [Table 1]. During this period, the wound steadily healed, and no other alternative treatment was given except *Calendula Q* for cleaning the wound.

## DISCUSSION

This case report describes the effectiveness of homoeopathic treatment in diabetic gangrene. The patient had sought homoeopathic treatment to avoid amputation. She continued her regular oral hypoglycaemic medication during treatment. She was advised to stop all other topical and oral medications before treatment and to avoid carbohydrate-rich foods.

Based on the totality of symptoms, the case was analysed. *Arsenic album* was selected as similimum based on marked restlessness which drives her from place to place, despair of recovery and forsaken feeling. It is also noted that *Arsenic* is one of the main remedies for burning pains at night, offensive discharging ulcers and gangrene.<sup>[9]</sup>

The gangrene was healed within 4 months and improvement in other general symptoms was also observed during the course of the treatment. After assessing the case with the Modified




Figure 1: Photographs of gangrene case (a-c) before treatment 9 July, 2021

Remedy Name	Ars	Merc	Sulph	Puls	Sil	Psor	Lach	Sep	Calc	Nat-c	Graph	Nit-ac	Plat	Am-c
<b>Totality</b>	16	11	9	9	9	9	8	8	7	6	6	6	5	5
<b>Symptom Covered</b>	9	6	6	5	5	4	6	5	4	5	4	4	4	3
[C] [Mind]Despair.Recovery:	3	2	1	1	1	2	1	2	3	1		1	1	1
[C] [Mind]Restlessness, nervousness:Tendency:Drives him from place to place:	2	1		1			2	1		1	1		1	2
[C] [Mind]Forsaken feeling:	1	2	1	3	1	3	2	1	1	2			2	
[C] [Generalities]Food and drinks:Meat:Desires:Sweets, and:	1		3							1				
[C] [Extremities]Gangrene:Diabetic:	1						1							
[C] [Extremities]Ulcers:Toes:	2	1	2		2		1	2		1	2	2	1	
[C] [Skin]Ulcers:Discharges:Offensive:Putrid:	3	2	1	3	3	3	1	2	2		1	2		2
[C] [Skin]Ulcers:Discharges:Watery:	2	3	1	1	2	1			1		2	1		
[C] [Generalities]Ulcers:Burning, as from glowing coals:	1													

Figure 2: Repertorial chart

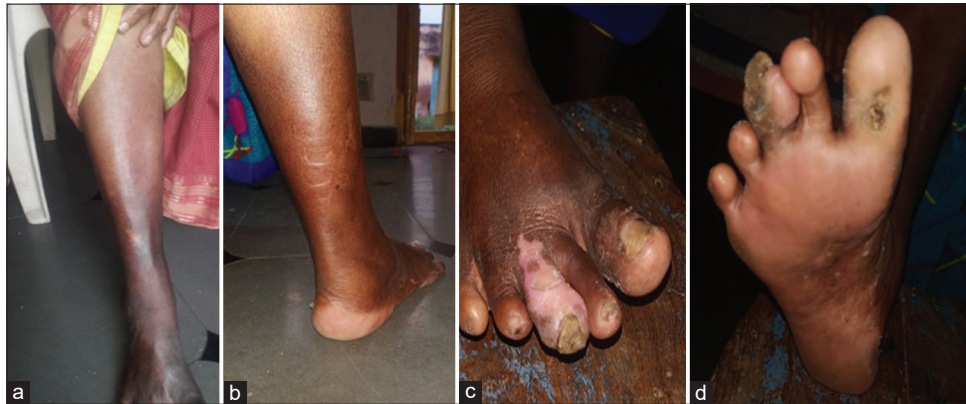Table 1: Observations and prescriptions

Date	Observations	Prescription
9 July, 2021	FBS - 181 mg/dL PPBS - 272 mg/dL HbA1c - 9.2% Dorsalis pedis and posterior tibial pulse not felt	Arsenic album 30 thrice daily for 2 days
13 July, 2021	The skin of right leg and foot has become dry and started peeling No blister Offensiveness of discharge and burning pain has reduced Blackish discoloration and swelling persist	Placebo twice daily for 5 days
18 July, 2021	Swelling and burning pain in foot and leg reduced Blackish discoloration in the proximal part of leg reduced Ulcer over big toe has reduced in its size Restlessness reduced Posterior tibial and dorsalis pedis pulse-feeble	Placebo twice daily for 1 month
19 August, 2021	Normal appearance of skin in proximal part of leg. Blackish discoloration persists in lower part of leg and foot Further reduction in size of the ulcer was seen [Figure 3]	Placebo twice daily for 20 days
9 September, 2021	The big toe and third toe ulcer improvement is seen No pain or burning sensation is complained FBS - 90 mg/dL, PPBS - 119 mg/dL	Placebo twice daily for 20 days
30 September, 2021	Normal appearance of skin in proximal part and distal part (partial) of the right leg Big toe and 3rd toe ulcers improved further Posterior tibial pulse - normal Dorsalis pedis pulse - slightly feeble	Placebo twice daily for 1 month
27 October, 2021	Normal appearance of skin on both upper and lower part of the leg 3rd toe ulceration healed completely Big toe ulcer almost closed with scab formation Pedal pulses - normal [Figure 4]	Placebo twice daily for 15 days
10 November, 2021	No new complaints HbA1c - 7.2%, RBS - 160 mg/dL	Placebo twice daily for 1 month
10 December, 2021	The patient is under regular observation FBS - 92 mg/dL, PPBS - 136 mg/dL	Placebo twice daily for 1 month

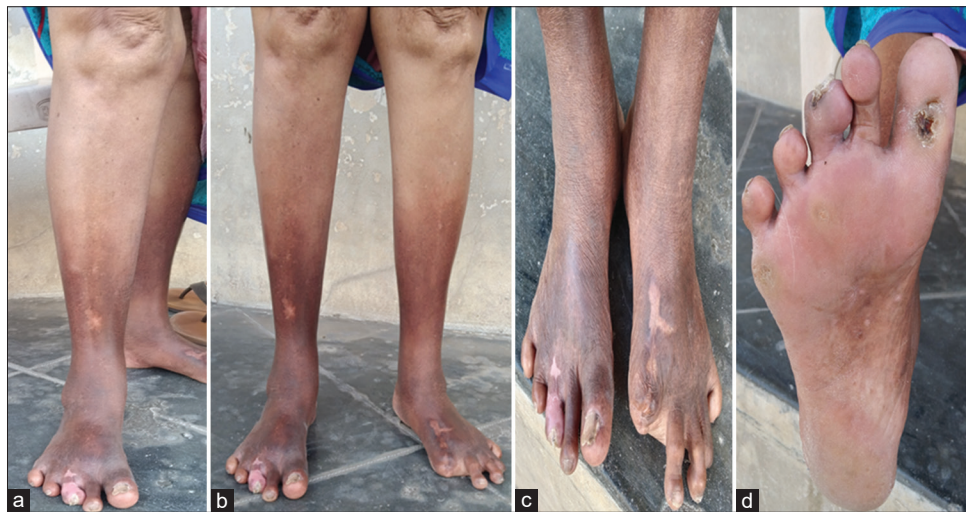FBS: Fasting blood sugar, PPBS: Postprandial blood sugar, HbA1c: Glycated haemoglobin, RBS: Random blood sugar

**Table 2: Assessment of outcome with Modified Naranjo criteria**

Scoring parameters	Yes	No	Not sure or N/A
Was there an improvement in the main symptom or condition for which the homeopathic medicine was prescribed?	+2		
Did the clinical improvement occur within a plausible time frame relative to the medicine intake?	+1		
Was there homoeopathic aggravation of symptoms?		0	
Did the effect encompass more than the main symptom or condition (i.e., were other symptoms not related to the main presenting complaint ultimately improved or changed)?	+1		
Did overall well-being improve?	+1		
Direction of cure: Did some symptoms improve in the opposite order of the development of symptoms of the disease?		0	
Direction of cure: Did at least one of the following aspects apply to the order of improvement of symptoms		0	
From organs of more importance to those of less importance			
From deeper to more superficial aspects of the individual			
From the top downwards			
Did 'old symptoms' (defined as non-seasonal and non-cyclical symptoms that were previously thought to have resolved) reappear temporarily during the course of improvement?		0	
Are there alternatives (other than the medicine) that with a high probability could have produced the improvement? (consider known course of disease, other forms of treatment and other clinically relevant interventions)		+1	
Was the health improvement confirmed by any objective evidence? (e.g., investigations and clinical examination)	+2		
Did repeat dosing, if conducted, create similar clinical improvement?			0
Total score – 08			



**Figure 3:** Photographs of gangrene case (a-d) during treatment: 19 August, 2021



**Figure 4:** Photographs of gangrene case (a-d) after treatment: 27 October, 2021

Naranjo criteria, the total score was 08 [Table 2].<sup>[10]</sup> It was suggestive of a definite association between the medicine and outcome.

The above case shows the usefulness of homoeopathic treatment in the management of diabetic wet gangrene and preservation of the limb from amputation.

In previously reported cases, surgical amputation of gangrene of the foot was prevented with homoeopathy. A similar case of gangrene has been reported, treated with *Secale cornutum* and had improved significantly.<sup>[6]</sup>

Mahesh *et al.* reported five cases treated with individualised homoeopathic medicine and regular dressing with *Calendula Q*. In all the patients, marked healing of gangrene was observed. Out of these five cases, in one case, *Arsenicum album* 12c was prescribed.<sup>[4]</sup> Another case report also reports *Arsenicum album* initiated improvement by stopping the spread of gangrene.<sup>[7]</sup> The above studies suggest that homoeopathic medicines can be used for treating gangrene cases.

The limitation of this case report is the inability to keep a record of the other investigations such as lipid profile, urea, creatinine and colour doppler, which could have been valuable indicators of the overall health condition of the patient.

## CONCLUSION

The case report shows that the surgical case of diabetic gangrene can be managed well with homoeopathic treatment. We can see the potential of homoeopathic remedies in treating such difficult cases. In this case, the gangrenous part was saved from amputation within a short period. Good control of blood glucose levels was noted along with improvement in the general condition of the patient. Thus, homoeopathy may be useful in treating lifestyle diseases like diabetes mellitus, especially where surgical intervention like amputation becomes the primary choice of treatment. In the future,

large sample size-based, randomised and controlled studies could confirm the effectiveness of homoeopathy in such cases.

## Declaration of patient consent

The patient has given her consent for reporting her clinical information in the journal. The patient understands that his name and initials will not be published, and due efforts will be made to conceal her identity, but anonymity cannot be guaranteed.

## Conflicts of interest

None declared.

## REFERENCES

1. Somen D. A Concise Textbook of Surgery. 11<sup>th</sup> ed. Kolkata: Das Publications; 2021. p. 235-6.
2. O'Connell PR, McCaskie AW, Sayers RD. Bailey and Love's Short Practice of Surgery. 24<sup>th</sup> ed. London: Edward Arnold Publishers Ltd; 2004. p. 938.
3. Papatheodorou K, Banach M, Bekiari E, Rizzo M, Edmonds M. Complications of diabetes 2017. J Diabetes Res 2018;2018:3086167.
4. Mahesh S, Mallapa M, Vithoulkas G. Gangrene: Five case studies of gangrene, preventing amputation through Homoeopathic therapy. Indian J Res Homoeopathy 2015;9:114-22.
5. Vibha SP, Kulkarni MM, Ballala AB, Kamath A, Maiya GA. Community based study to assess the prevalence of diabetic foot syndrome and associated risk factors among people with diabetes mellitus. BMC Endocr Disord 2018;18:43.
6. Ali MS, Bindu PH. A case of diabetic foot gangrene. Indian J Res Homoeopathy 2007;1:42-51.
7. Murthy K, Murthy DA. A case on diabetic foot gangrene. Homoeopathic Links 2017;30:259-61.
8. Shah J. Homopath Classic Application, 8.0 Version. Maharashtra: Mind Technologies Pvt Ltd; 2002.
9. Kent J. Lectures on Homoeopathic Materia Medica. New Delhi: Jain Publishing Company; 2012. p. 149-51.
10. Lamba CD, Gupta VK, van Haselen R, Rutten L, Mahajan N, Molla AM, *et al.* Evaluation of the modified Naranjo criteria for assessing causal attribution of clinical outcome to homeopathic intervention as presented in case reports. Homeopathy 2020;109:191-7.

## Éviter l'amputation chirurgicale de la gangrène diabétique grâce à l'homéopathie – Un rapport de cas

**Introduction:** La gangrène est définie comme la décomposition ou la mort d'un organe ou d'un tissu en raison d'un apport sanguin compromis. C'est une condition périlleuse et mortelle survenant le plus souvent en raison du diabète. En règle générale, les personnes atteintes de diabète ont un risque significativement accru de gangrène des membres inférieurs entraînant une amputation.

**Résumé du cas:** Une femme de 70 ans présente une gangrène diabétique de la jambe et du pied droits depuis 4 mois. Le patient s'est plaint d'un gonflement et d'une décoloration noirâtre du pied et de la jambe droits avec des ulcérations offensives sur les premier et troisième orteils. On lui a diagnostiqué une gangrène du pied diabétique et on lui a conseillé de subir une amputation chirurgicale du pied et un débridement de la jambe par un chirurgien local dans les 4 à 5 jours pour arrêter la propagation de la gangrène. Après des résultats insatisfaisants, le patient s'est tourné vers l'homéopathie pour éviter l'amputation. Après une prise de cas détaillée, une analyse et une répertorisation, *Arsenic album 30C* a été prescrit. En 3-4 mois, il y a eu une amélioration du membre sans aucune intervention chirurgicale. *Calendula officinalis Q* a été utilisé pour le nettoyage de la plaie et un pansement régulier. Ce cas illustre l'importance de la médecine homéopathique individualisée dans le traitement efficace de la gangrène, évitant ainsi l'amputation.

## Verhinderung einer chirurgischen Amputation bei diabetischem Gangrän durch Homöopathie - ein Fallbericht

**Einleitung:** Gangrän ist definiert als der Zerfall oder Tod eines Organs oder Gewebes aufgrund einer beeinträchtigten Blutversorgung. Es handelt sich um einen gefährlichen und tödlichen Zustand, der am häufigsten durch Diabetes verursacht wird. Im Allgemeinen haben Menschen mit Diabetes ein deutlich erhöhtes Risiko für eine Gangrän der unteren Extremitäten, die zu einer Amputation führt.

**Zusammenfassung des Falles:** Eine 70-jährige Frau stellte sich mit diabetischem Gangrän des rechten Beins und Fußes seit 4 Monaten vor. Die Patientin klagte über Schwellungen und eine schwärzliche Verfärbung des rechten Fußes und Beins mit offensiv auslaufenden Geschwüren an der ersten und dritten Zehe. Es wurde eine diabetische Fußgangrän diagnostiziert und ihr geraten, sich innerhalb von 4-5 Tagen einer chirurgischen Amputation des Fußes und einem Debridement des Beins durch einen örtlichen Chirurgen zu unterziehen, um die Ausbreitung der Gangrän zu verhindern. Nach einem unbefriedigenden Ergebnis wandte sich die Patientin an die Homöopathie, um eine Amputation zu vermeiden. Nach einer ausführlichen Fallaufnahme, Analyse und Repertorisation wurde *Arsenic album 30C* verordnet. Innerhalb von 3-4 Monaten kam es zu einer Besserung der Gliedmaße ohne chirurgischen Eingriff. *Calendula officinalis Q* wurde zur Reinigung der Wunde und für regelmäßige Verbände verwendet. Dieser Fall zeigt, wie wichtig eine individuelle homöopathische Behandlung ist, um Gangrän wirksam zu behandeln und eine Amputation zu vermeiden.

## होम्योपैथी के माध्यम से डायबिटिक गैंग्रीन के सर्जिकल विच्छेदन से छुटकारा – एक केस रिपोर्ट

**परिचय:** रक्त आपूर्ति क्षतिग्रस्त हो जाने के कारण किसी अंग या ऊतक की क्षय या मृत्यु हो जाने को गैंग्रीन कहा जाता है। यह डायबिटीज के कारण होने वाली एक खतरनाक और घातक है। आमतौर पर, डायबिटीज से ग्रस्त लोगों में पैरों में गैंग्रीन का खतरा काफी बढ़ जाता है, जिससे अंगों का विच्छेदन करना पड़ता है।

**केस सारांश:** एक 70 वर्षीय महिला ने दाहिने पैर और टाँग में 4 महीने से डायबिटिक गैंग्रीन की शिकायत के बारे में बताया। रोगी ने दाहिने पैर में सूजन और रंग काला हो जाने और पैर की पहली और तीसरी उंगलियों पर दुर्गंधित निर्वहन अल्सर की शिकायत की। रोगी का रोगनिदान डायबिटिक फुट गैंग्रीन किया गया था और गैंग्रीन को बढ़ने से रोकने के लिए 4-5 दिनों में सर्जरी के माध्यम से पैर का विच्छेदन करवाने की सलाह एक स्थानीय सर्जन द्वारा दी गई थी। असंतोषजनक परिणाम के कारण, रोगी ने विच्छेदन से बचने के लिए होम्योपैथी का सहारा लिया। प्रकरण को विस्तार से समझने, विश्लेषण और रिपोर्टाइजेशन के बाद, *आर्सेनिक एल्बम 30C* का सेवन करने के लिए कहा गया, 3-4 महीनों में अंदर, बिना किसी सर्जिकल हस्तक्षेप के अंग में सुधार होना शुरू हो गया। *केलेनड्युला ऑफिसिनेलिस Q* का उपयोग घाव को साफ करने और नियमित ड्रेसिंग के लिए किया गया। इस केस से गैंग्रीन के प्रभावी इलाज में व्यक्तिगत रूप से चयनित होम्योपैथिक दवा के महत्व का पता चलता है, जिससे विच्छेदन से बचा जा सकता है।



## Obviar la amputación quirúrgica de la gangrena diabética a través de la homeopatía - Un informe de caso

**Introducción:** La gangrena se define como la descomposición o muerte de un órgano o tejido debido a un suministro de sangre comprometido. Es una condición peligrosa y fatal que ocurre más comúnmente debido a la diabetes. En general, las personas con diabetes tienen un riesgo significativamente mayor de gangrena de las extremidades inferiores que conduce a la amputación.

**Resumen del caso:** Mujer de 70 años que presentó gangrena diabética de la pierna derecha y el pie desde hace 4 meses. El paciente se quejó de hinchazón y decoloración negra del pie derecho y la pierna con úlceras ofensivas de descarga en el primer y tercer dedo del pie. Le diagnosticaron gangrena del pie diabético y se le aconsejó que se sometiera a una amputación quirúrgica del pie y al desbridamiento de la pierna por un cirujano local dentro de los 4-5 días para detener la propagación de la gangrena. Después de un resultado insatisfactorio, el paciente recurrió a la homeopatía para evitar la amputación. Después de una toma de casos detallada, análisis y repertorización, se prescribió Arsenic album 30C. Dentro de 3-4 meses, hubo una mejoría en la extremidad sin ninguna intervención quirúrgica. Calendula officinalis Q se utilizó para limpiar la herida y el vendaje regular. Este caso describe la importancia de la medicina homeopática individualizada en el tratamiento eficaz de la gangrena, evitando así la amputación.

## 通过顺势疗法减轻糖尿病坏疽的手术截肢- 病例研究

**简介:** 坏疽是指由于血液供应受损导致的器官或组织的腐烂或死亡。这是一种危险和致命的疾病，最常见的原因是糖尿病。一般来说，糖尿病患者下肢坏疽导致截肢的风险显著增加。

**病例摘要:** 一名70岁的女性自4个月以来，右腿和右脚出现糖尿病性坏疽。患者抱怨右脚和腿肿胀和发黑，第一和第三脚趾上有令人厌恶的排出性溃疡。她被诊断为糖尿病足坏疽，并建议当地外科医生在4-5天内进行足部手术截肢和腿部清创术，以阻止坏疽的蔓延。在不满意的结果后，患者转为顺势疗法以避免截肢。经过详细的病例采集、分析和再灌注，开具了砷专辑30C。在3-4个月内，在没有任何手术干预的情况下，四肢得到了改善。金盏花Q用于清洁伤口和常规敷料。本病例描述了个体化顺势疗法药物在有效治疗坏疽从而避免截肢方面的重要性。