

28-6-2023

Recurrent appendicitis treated with the homoeopathic medicine Iris tenax 30C: A case report

Vinitha Edavattath Ramanan

National Homoeopathy Research Institute in Mental Health, Kottayam, Kerala, India, drvinithasajeev@gmail.com

Shareena CP

National Homoeopathy Research Institute in Mental Health, Kottayam, Kerala, India, shareenaussi@hotmail.com

Follow this and additional works at: <https://www.ijrh.org/journal>

 Part of the [Homeopathy Commons](#)

How to cite this article

Edavattath Ramanan V, CP S. Recurrent appendicitis treated with the homoeopathic medicine Iris tenax 30C: A case report. Indian J Res Homoeopathy 2023;17(2):63-69. doi: [10.53945/2320-7094.1129](https://doi.org/10.53945/2320-7094.1129)

This Case Report is brought to you for free and open access by Indian Journal of Research in Homoeopathy. It has been accepted for inclusion in Indian Journal of Research in Homoeopathy by an authorized editor of Indian Journal of Research in Homoeopathy. For more information, please contact ijrhonline@gmail.com.



Recurrent appendicitis treated with the homoeopathic medicine Iris tenax 30C: A case report

Abstract

Introduction: The non-acute variants of appendicitis include recurrent, subacute, and chronic appendicitis, which are rarely diagnosed and remain subjects of case reports. The diagnosis is complex and is based on history, clinical examination, and an ultrasonogram or computed tomography. Unlike the acute variety, a surgical emergency, these cases do not require immediate surgery. In the present case, the patient had pain in the right lower quadrant (RLQ) of the abdomen in January 2021, which was relieved with conventional medications. However, the pain recurred after 2½ months and was diagnosed as recurrent appendicitis. **Case Summary:** This case of recurrent appendicitis was treated from April to August 2021 at the National Homoeopathy Research Institute in Mental Health, Kottayam, Kerala, with the homoeopathic medicine Iris tenax (Iris-t). The patient presented with pain in the RLQ of the abdomen with mild to moderate tenderness. There was a marked improvement in symptoms of appendicitis in the 2nd week of starting homoeopathic treatment. Modified Naranjo Criteria for Homoeopathy–, a causal attribution inventory score, was used to assess the likelihood of attribution of the clinical outcome to homoeopathic medicine as per HOM-CASE guidelines. The ultrasonography report showed no evidence of appendicitis after treatment. The MONARCH score of +8/13 indicated a probable causal relationship between the medicine prescribed and the treatment outcome. The present case report shows the possible usefulness of the homoeopathic medicine Iris-t in cases with appendix pathology.

Acknowledgments and Source of Funding

We express our sincere gratitude to Dr. K. C. Muraleedharan, Asst. Director, Officer-in-Charge, NHRIMH Kottayam, for his motivation and institutional support. We thank Prof. Dr. K. Sudheer, MD, FRCR, Consultant Radiologist, for his valuable guidance and expert opinion on the case. We also thank the patient for his kind consent to the publication of the treatment results.

Recurrent appendicitis treated with the homoeopathic medicine *Iris tenax* 30C: A case report

Vinitha Edavattath Ramanan*, Shareena C P

National Homoeopathy Research Institute in Mental Health, Kottayam, Kerala, India

Abstract

Introduction: The non-acute variants of appendicitis include recurrent, subacute, and chronic appendicitis, which are rarely diagnosed and remain subjects of case reports. The diagnosis is complex and is based on history, clinical examination, and an ultrasonogram or computed tomography. Unlike the acute variety, a surgical emergency, these cases do not require immediate surgery. In the present case, the patient had pain in the right lower quadrant (RLQ) of the abdomen in January 2021, which was relieved with conventional medications. However, the pain recurred after 2½ months and was diagnosed as recurrent appendicitis. **Case Summary:** This case of recurrent appendicitis was treated from April to August 2021 at the National Homoeopathy Research Institute in Mental Health, Kottayam, Kerala, with the homoeopathic medicine *Iris tenax* (*Iris-t*). The patient presented with pain in the RLQ of the abdomen with mild to moderate tenderness. There was a marked improvement in symptoms of appendicitis in the 2nd week of starting homoeopathic treatment. Modified Naranjo Criteria for Homoeopathy–, a causal attribution inventory score, was used to assess the likelihood of attribution of the clinical outcome to homoeopathic medicine as per HOM-CASE guidelines. The ultrasonography report showed no evidence of appendicitis after treatment. The MONARCH score of +8/13 indicated a probable causal relationship between the medicine prescribed and the treatment outcome. The present case report shows the possible usefulness of the homoeopathic medicine *Iris-t* in cases with appendix pathology.

Keywords: Case report, Homoeopathy, *Iris tenax*, Recurrent appendicitis

INTRODUCTION

The vermiform appendix is a vestigial organ. Its importance is due only to its propensity for inflammation, which results in the clinical syndrome known as acute appendicitis.^[1] The non-acute variants of appendicitis include recurrent, subacute, and chronic appendicitis, which are rarely diagnosed and remain subjects of case reports.^[2] Some episodes of acute appendicitis subside before they reach the critical stage and are called subacute appendicitis. This condition may recur.^[3]

Chronic and recurrent appendicitis are uncommon presentations of disease of the appendix. The diagnosis is complex and is based on history, clinical examination, and an ultrasonogram or computed tomography scan. Unlike the acute variety, which is a surgical emergency, chronic cases do not require immediate surgery.^[4]

In a systematic review of the population-based study, the incidence of appendicitis is stable in most Western countries, ranging from 100 to 150 cases/100000 population. The

incidence of newly industrialized countries is unknown due to data scarcity.^[5] The incidence of recurrent and chronic appendicitis is 10% and 1%, respectively.^[6] Compared to acute appendicitis, the relatively lower severity of recurrent and chronic appendicitis makes it a lesser-diagnosed condition in clinical practice. The terms ‘recurrent’ and ‘chronic’ appendicitis are used interchangeably in the literature.^[7] Recurrent episodes of pain in the right lower quadrant (RLQ) of the abdomen of a longer duration may indicate recurrent appendicitis and need thorough investigation. In chronic appendicitis, the pain lasts more than 3 weeks. There may not be associated inflammatory changes.^[7] Acute appendicitis is a life-threatening abdominal surgical emergency that requires prompt intervention.^[8,9]

***Address for correspondence:** Dr. Vinitha Edavattath Ramanan, National Homoeopathy Research Institute in Mental Health, Kottayam, Kerala, India.
E-mail: vinitha_sajeev@yahoo.co.in

Received: 18 January 2023; **Accepted:** 12 June 2023

Access this article online

Quick Response Code:



Website:
www.ijrh.org

DOI:
10.53945/2320-7094.1129

This is an open access journal, and articles are distributed under the terms of the Creative Commons Attribution-NonCommercial-ShareAlike 4.0 License, which allows others to remix, tweak, and build upon the work non-commercially, as long as appropriate credit is given and the new creations are licensed under the identical terms.

How to cite this article: Vinitha ER, Shareena CP. Recurrent appendicitis treated with the homoeopathic medicine *Iris tenax* 30C: A case report. Indian J Res Homoeopathy 2023;17:63-69.

The symptoms of acute appendicitis include periumbilical colic, pain shifts to the right iliac fossa, anorexia, and nausea. Clinical signs of appendicitis are pyrexia, localized tenderness in the right iliac fossa, muscle guarding, and rebound tenderness.^[1] In recurrent appendicitis, there are one or more episodes of acute appendicitis, and the symptoms subside spontaneously. In chronic appendicitis, the pain is less severe but continuous and lasts for more than 2 days. It may extend for months or years.^[4] Imaging techniques for diagnosis include radiography, ultrasound, and contrast-enhanced computed tomography (CT). Helical CT has reported a sensitivity that may reach 95% and a specificity higher than 95%.^[10]

The prognosis of untreated appendicitis is unknown because randomized controlled trials comparing treatment with no treatment would be unethical. However, spontaneous resolution and recurrence of appendicitis remain contentious issues among surgeons. According to modern medicine, the current standard treatment for uncomplicated appendicitis is usually surgical removal of the appendix (appendectomy) to prevent potential complications. But studies show postoperative complications in both open and laparoscopic surgeries.^[11]

In the present case, the patient had the first episode of pain in January 2021, which was relieved with conventional medications. However, the pain recurred after 2½ months. So, the diagnosis of recurrent appendicitis was considered. The therapeutic use of *Iris tenax* (*Iris ten.*) in appendicitis is clinically verified by a multicentric clinical verification study by CCRH.

This case is being reported according to the HOM-CASE guidelines.^[12]

PATIENT INFORMATION

A 71-year-old Indian male farmer presented to the outpatient department of the National Homoeopathy Research Institute in Mental Health, Kottayam, Kerala, on April 16, 2021, with pain in the right side of the lower abdomen. The pain had been there for 2 days when he reported it to the outpatient department (OPD). He had a similar pain episode in the abdomen 2½ months ago. The patient was diagnosed with subacute appendicitis in January 2021 [Figure 1] and was on standard conventional medications for relief. Nevertheless, given the recurring condition, the patient opted for the homoeopathic treatment.

During case taking, the patient reported pain in the right-side lower abdomen, difficulty passing stool, increased thirst, and a loss of appetite. He was hypertensive and had been under conventional treatment for 2 years. There was no significant family history of any disease.

Clinical findings

On general examination, there were no signs of acute inflammation. Physical examination elicited mild to moderate tenderness at McBurney’s point.

Laboratory findings dated 16 April 2021 were hemoglobin: 9.7 g/dL, total white blood cell count: 6500 cells/mm³,

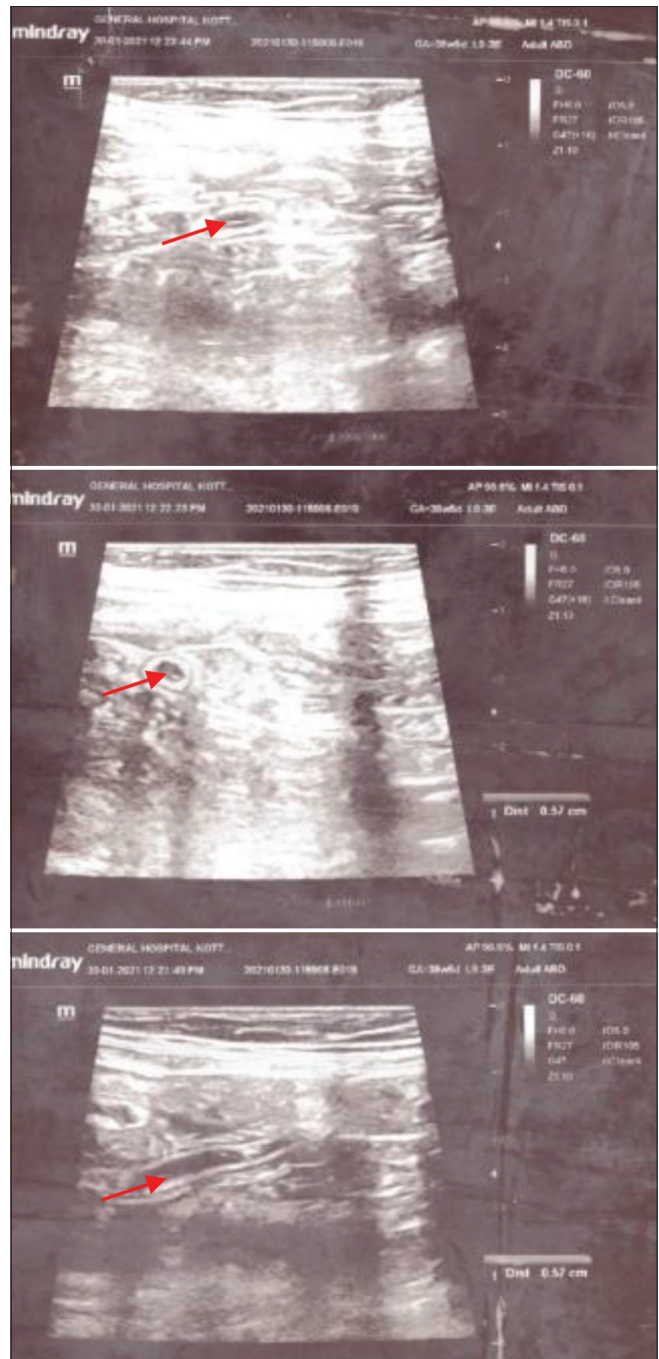


Figure 1: Ultrasonography showing prominent appendix before treatment

lymphocytes - 32%, mid-sized cells - 11%, granulocytes - 57%, erythrocyte sedimentation rate: 54 mm/h, platelet count: 199 × 10³/μL, total red blood cells: 3.6 × 10³/μL, and C-reactive protein was negative.

USG of the abdomen indicated mild probe tenderness in the right iliac fossa, and a prominent appendicular loop of 5.7 mm, giving the impression of subacute appendicitis.

Therapeutic intervention

The selection of medicine was based on the following totality of symptoms:

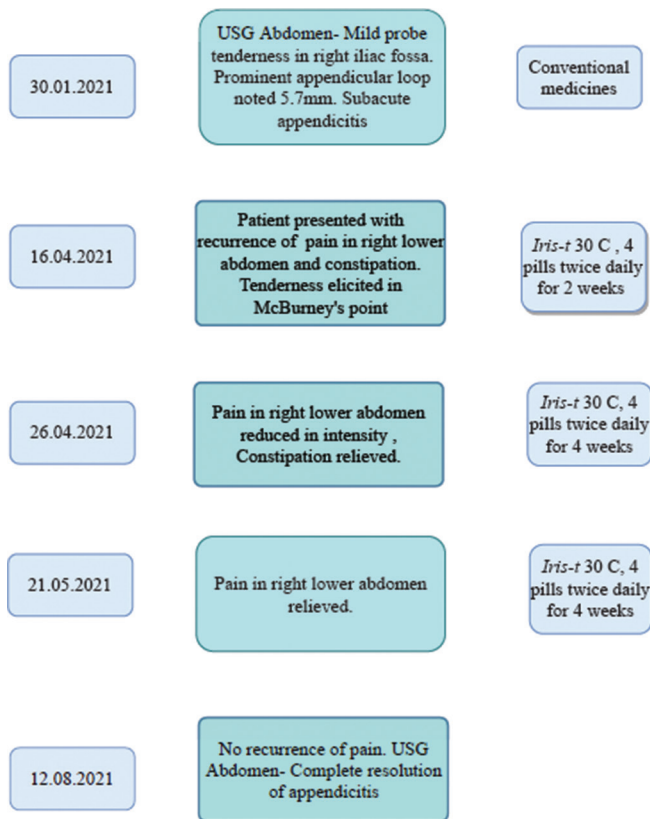


Figure 2: Flow chart showing the timeline of treatment

- Increased thirst
- Loss of appetite
- Constipation
- Pain in the right lower quadrant of the abdomen
- Appendicitis

Iris ten. 30C was dispensed in globules of size forty; four globules were to be taken twice daily. The patient was advised to report to OPD after 2 weeks. All medicines were procured from the institute pharmacy and manufactured by the Kerala State Homoeopathic Cooperative Pharmacy, Kerala.

Follow-up and outcome

After 2 weeks of medication, the patient reported that the pain in the right-side lower abdomen had reduced in intensity and that the difficulty in passing stool was better. However, since the episodes of abdominal pain persisted, even though in mild intensity, *Iris ten. 30C* was prescribed to be taken twice daily for 4 weeks. After 1 month, the patient reported relief from the abdominal pain. The difficulty in stool passage was also relieved, but the appetite remained low. The same medicine was then prescribed for another month, considering the recurrent nature of the condition. A USG abdomen done after 3 months of homoeopathic treatment showed no evidence of appendicitis.

Thus, the patient was treated in our OPD normally for about 4 months and was regularly monitored for recurrence, and all the symptoms were relieved eventually [Figure 2].

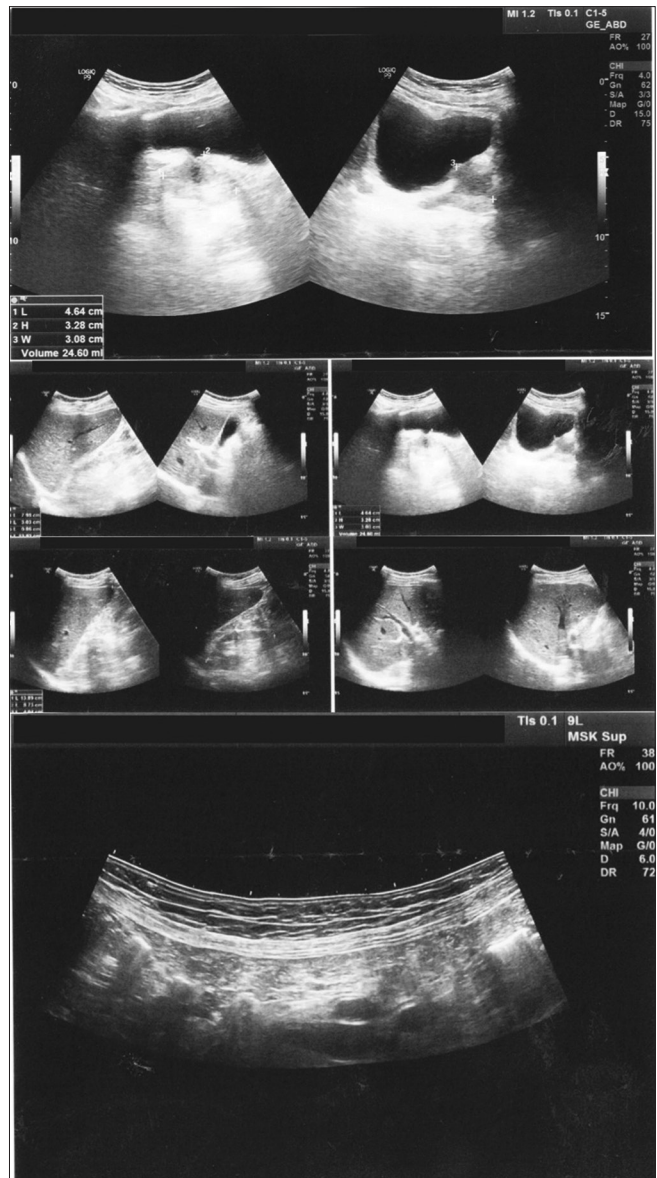


Figure 3: Ultrasonography showing normal appendix after treatment

The MONARCH score was used to assess the causal attribution of the clinical outcome to homoeopathic medicine. The score of +8/13 indicated a probable causal relationship between the medicine prescribed and the treatment outcome [Table 1].^[13]

The homoeopathic medicine *Iris ten. 30C* was prescribed on the basis of pathology alone. As examined clinically, there was an improvement in the abdominal pain right from the 1st week of medication. The repeated USG showed no impression of appendicitis [Figure 3].

DISCUSSION

The patient presented with mild to moderate tenderness and pain in the RLQ of the abdomen, which was the second such episode. During the first episode, which occurred 2½ months ago, the USG abdomen showed features of

Table 1: MONARCH Inventory (improved version of the Modified Naranjo criteria for Homoeopathy)

S. No.	Domain	Yes	No	Not sure or N/A
1	Was there an improvement in the main symptom or condition for which the homeopathic medicine was prescribed?	+2	-1	0
2	Did the clinical improvement occur within a plausible time frame relative to the medicine intake?	+1	-2	0
3	Was there a homoeopathic aggravation of symptoms?	+1	0	0
4	Did the effect encompass more than the main symptom or condition (i.e., were other symptoms, not related to the main presenting complaint, improved or changed)?	+1	0	0
5	Did overall well-being improve? (Suggest using a validated scale or mention about changes in physical, emotional, and behavioral elements)	+1	0	0
6a	Direction of cure: did some symptoms improve in the opposite order of the development of symptoms of the disease?	+1	0	0
6b	Direction of cure: did at least one of the following aspects apply to the order of improvement in symptoms: <ul style="list-style-type: none"> • From organs of more importance to those of less importance? • From deeper to more superficial aspects of the individual? • From the top downwards? 	+1	0	0
7	Did “old symptoms” (defined as non-seasonal and non-cyclical symptoms that were previously thought to have resolved) reappear temporarily during the course of improvement?	+1	0	0
8	Are there alternative causes (i.e., other than the medicine) that—with a high probability—could have produced the improvement? (Consider known course of disease, other forms of treatment, and other clinically relevant)	-3	+1	0
9	Was the health improvement confirmed by any objective evidence? (e.g., investigations, clinical examination, etc.)	+2	0	0
10	Did repeat dosing, if conducted, create similar clinical improvement?	+1	0	0
Total score: +8				

*The numbers in bold font represent the option selected

subacute appendicitis, which was treated with conventional medications for pain. In peer-reviewed journals, there are case reports and case series on similar pain in the RLQ of the abdomen. In these reported cases, the patients underwent appendectomy with complete relief of pain.^[7,14] Unlike those cases, the patient in the present case was treated with the homoeopathic medicine *Iris ten.* 30C, a known remedy for appendicitis.^[15] The pain was better when the patient reported it after 2 weeks.

In a multicentric clinical verification study, Chakraborty *et al.* verified the therapeutic use of *Iris ten.* for appendicitis, as mentioned in the literature. All the patients during the clinical verification of *Iris ten.* reported excessive thirst. Pain in the right iliac region with excessive thirst comes out as the chief symptom of the drug.^[16] In the case reported here, the patient had presented with increased thirst, loss of appetite, constipation, pain in the right iliac region, and appendicitis, which were all clinically verified.^[16]

Iris ten. belongs to the plant kingdom of the family Iridaceae.^[17] The medicine was prescribed in 30C potency, depending upon the susceptibility and seat of the disease. According to Stuart Close, susceptibility diminishes with age, and medication with a peculiar affinity for organs should be given in medium or higher potencies.^[18]

The patient’s presenting complaints of pain in the RLQ of the abdomen and associated complaints improved with *Iris ten.* within 2 weeks. The patient did not take any other medications for pain during this treatment. The improvement was also verified objectively by the disappearance of pathology in the ultrasonography scan review. A senior radiologist reviewed and confirmed the USG findings before and after the homoeopathic treatment. The MONARCH score of +8 also indicated the probable causal role of the medicine *Iris ten.* in recovery [Table 1].

This case, thus, throws light on the possible use of homoeopathic medicine *Iris ten.* in the treatment of recurrent appendicitis and also the significance of clinical verification of lesser-proven, rare medications for subsequent prescription by clinicians in daily practice.

Evidence-based medicine (EBM) enables the use of the best evidence to make sound patient care decisions. The practice of EBM generates clinically essential information on the prognosis, diagnosis, and treatment of different disease conditions. Such information from various case studies enables critical analysis for formulating the research questions of controlled trials. It is hoped that this case report will contribute to similar evidence-based efforts.^[19]

CONCLUSION

The present case report shows the possible usefulness of homoeopathic medicine *Iris ten.* in cases presenting with recurring pain in the RLQ, suggesting appendix pathology.

ACKNOWLEDGEMENT

We express our sincere gratitude to Dr. K. C. Muraleedharan, Asst. Director, Officer-in-Charge, NHRIMH Kottayam, for his motivation and institutional support. We thank Prof. Dr. K. Sudheer, MD, FRCR, Consultant Radiologist, for his valuable guidance and expert opinion on the case. We also thank the patient for his kind consent to the publication of the treatment results.

Declaration of patient consent

The patient gave verbal consent to publish his treatment results in this case report.

Financial support and sponsorship

Nil.

Conflicts of interest

None declared.

REFERENCES

- Williams NS, Bulstrode CJ, O'Connell PR. Bailey and Love's Short Practice of Surgery. 26th ed. United States: CRC Press; 2013.
- Gómezo-Torres GA, Ortega-García OS, Gutierrez-López EG, Carballido-Murguía CA, Flores-Rios JA, Lopez-Lizarraga CR, *et al.* A rare case of subacute appendicitis, actinomycosis as the final pathology reports: A case report and literature review. *Int J Surg Case Rep* 2017;36:46-9.
- Das S. A Concise Textbook of Surgery. 5th ed. Kolkata: Dr. Somen Das Publications; 2008. p. 350-1.
- Kothadia JP, Katz S, Ginzburg L. Chronic appendicitis: Uncommon cause of chronic abdominal pain. *Therap Adv Gastroenterol* 2015;8:160-2.
- Ferris M, Quan S, Kaplan BS, Molodecky N, Ball CG, Chernoff GW, *et al.* The global incidence of appendicitis: A systematic review of population-based studies. *Ann Surg* 2017;266:237-41.
- Mengesha MD, Teklu GG. A case report on recurrent appendicitis: An often forgotten and atypical cause of recurrent abdominal pain. *Ann Med Surg (Lond)* 2018;28:16-9.
- Lee CK, Pelenyi SS, Fleites O, Velez V, Alaimo KL, Ramcharan DN, *et al.* Chronic appendicitis, the lesser-known form of appendiceal inflammation: A case report. *Cureus* 2021;13:e19718.
- Humes DJ, Simpson J. Clinical review: Acute appendicitis. *BMJ* 2006;333:530-4.
- Andiran F, Dayi S, Caydere M, Huseyin U. Chronic recurrent appendicitis in children: An insidious and neglected cause of surgical abdomen. *Turk J Med Sci* 2002;32:351-4.
- Petroianu A. Diagnosis of acute appendicitis. *Int J Surg* 2012;10:115-9.
- Agrawal SN, Meshram S, Dhruv K. Study of laparoscopic appendectomy: Advantages, disadvantages and reasons for conversion of laparoscopic to open appendectomy. *Int Surg J* 2017;4:993-7.
- Van Haselen RA. Homeopathic clinical case reports: Development of a supplement (HOM-CASE) to the CARE clinical case reporting guideline. *Complement Ther Med* 2016;25:78-85.
- Lamba CD, Gupta VK, van Haselen R, Rutten L, Mahajan N, Molla AM, *et al.* Evaluation of the modified Naranjo criteria for assessing causal attribution of clinical outcome to Homeopathic intervention as presented in case reports. *Homeopathy* 2020;109:191-7.
- Mattei P, Sola JE, Yeo CJ. Chronic and recurrent appendicitis are uncommon entities often misdiagnosed. *J Am Coll Surg* 1994;178:385-9.
- Boericke W. Boericke's New Manual of Homeopathic Materia Medica with Repertory. 3rd Revised and Augmented ed. New Delhi: B. Jain Publishers Pvt Ltd.; 2018. p. 355.
- Chakraborty PS, Khurana A, Vichitra AK, Chakraborty D, Singh DK, Singh H, *et al.* Iris Tenax - A multicentric clinical verification study. *Indian J Res Homoeopathy* 2010;4:18-22.
- Clark JH. A Dictionary of Practical Materia Medica. Vol. 2. New Delhi: B. Jain Publishers (P) Ltd.; 2006. p. 47.
- Close SM. Homeopathic Posology. *Genius of Homeopathy: Lectures and Essays on Homeopathic Philosophy with Word Index*. 2nd ed. New Delhi: B Jain; 2004. p. 240.
- Masic I, Miokovic M, Muhamedagic B. Evidence-based medicine - new approaches and challenges. *Acta Inform Med* 2008;16:219-25.

Appendicite récurrente traitée avec la médecine homéopathique Iris tenax 30C: Un rapport de cas

L'Introduction: Les variantes non mignonnes de l'appendicite comprennent l'appendicite récurrente, subaiguë et chronique, qui sont rarement diagnostiquées et font toujours l'objet de rapports de cas. Le diagnostic est complexe et repose sur les antécédents, l'examen clinique et l'échographie ou la TDM. Contrairement à la variété aiguë, une urgence chirurgicale, ces cas ne nécessitent pas de chirurgie immédiate. Dans le cas présent, la patiente avait des douleurs dans le quadrant inférieur droit [QR] de l'abdomen en janvier 2021, qui ont été soulagées par des médicaments conventionnels. Cependant, la douleur s'est répétée après deux mois et demi. Ainsi, le diagnostic d'appendicite récurrente est suggéré.

Résumé du cas: Ce cas d'appendicite récurrente a été traité d'avril à août 2021 au National Homoeopathy Research Institute in Mental Health Kottayam Kerala, sous l'égide du Central Council for Research in Homoeopathy [CCRH] India avec la médecine homéopathique Iris-Tenax [Iris-t]. Ce cas a présenté des douleurs dans le quadrant inférieur droit (RLQ) de l'abdomen avec une sensibilité légère à modérée. Il y avait une amélioration marquée des symptômes de l'appendicite dans la deuxième semaine du début du traitement homéopathique. Les critères modifiés de Naranjo pour l'homéopathie, un score d'inventaire de l'attribution causale, ont évalué la probabilité d'attribution du résultat clinique à la médecine homéopathique conformément aux lignes directrices du CDM-CASE. Le rapport d'échographie n'a montré aucun signe d'appendicite après le traitement. Le score MONARCH de +8/13 indique une relation causale probable entre le médicament prescrit et le résultat du traitement. Le présent rapport de cas montre l'utilité possible de la médecine homéopathique Iris-t dans les cas avec une pathologie annexe.

Rezidivierende Blinddarmentzündung behandelt mit dem homöopathischen Arzneimittel *Iris tenax* 30C: Ein Fallbericht

Einleitung: Zu den nicht akuten Varianten der Appendizitis gehören die rezidivierende, die subakute und die chronische Appendizitis, die selten diagnostiziert werden und Gegenstand von Fallberichten bleiben. Die Diagnose ist komplex und stützt sich auf Anamnese, klinische Untersuchung und Ultraschall oder CT. Anders als bei der akuten Form, die einen chirurgischen Notfall darstellt, ist in diesen Fällen keine sofortige Operation erforderlich. Im vorliegenden Fall hatte der Patient im Januar 2021 Schmerzen im rechten unteren Quadranten [RLQ] des Abdomens, die mit herkömmlichen Medikamenten gelindert wurden. Nach zweieinhalb Monaten traten die Schmerzen jedoch erneut auf. Daher wird die Diagnose einer rezidivierenden Appendizitis gestellt.

Zusammenfassung des Falles: Dieser Fall von rezidivierender Appendizitis wurde von April bis August 2021 im Nationalen Homöopathie-Forschungsinstitut für geistige Gesundheit in Kottayam, Kerala, im Rahmen des Central Council for Research in Homoeopathy [CCRH] India mit dem homöopathischen Arzneimittel *Iris-Tenax* [Iris-t] behandelt. Dieser Fall wurde mit Schmerzen im rechten unteren Quadranten (RLQ) des Abdomens mit leichter bis mittlerer Empfindlichkeit vorgestellt. In der zweiten Woche nach Beginn der homöopathischen Behandlung kam es zu einer deutlichen Besserung der Symptome einer Appendizitis. Die modifizierten Naranjo-Kriterien für die Homöopathie, ein Kausalattributionsinventar, bewertete die Wahrscheinlichkeit der Zuordnung des klinischen Ergebnisses zur homöopathischen Arznei gemäß den HOM-CASE-Richtlinien. Der Ultraschallbericht zeigte keine Anzeichen einer Appendizitis nach der Behandlung. Der MONARCH-Score von +8/13 deutete auf einen wahrscheinlichen Kausalzusammenhang zwischen der verordneten Arznei und dem Behandlungsergebnis hin. Der vorliegende Fallbericht zeigt den möglichen Nutzen der homöopathischen Arznei *Iris-t* in Fällen mit einer Blinddarmopathie.

होम्योपैथिक दवा आईरिस टेनैक्स 30C से बार-बार होने वाले एपेंडिसाइटिस का उपचार: एक केस रिपोर्ट

परिचय: एपेंडिसाइटिस के सामान्य प्रकारों में बार-बार होने वाले, सबएक्यूट और क्रोनिक एपेंडिसाइटिस शामिल हैं, जिनका निदान बहुत कम ही होता है और ये केस रिपोर्ट के विषय रहते हैं। इनका निदान करना जटिल होता है और वृतांत चिकित्सकीय जांच और अल्ट्रासोनोग्राम या CT पर आधारित होता है। इन मामलों में तत्काल शल्यचिकित्सक की आवश्यकता नहीं होती जैसा कि एक्यूट प्रकार में होता है। मौजूदा मामले में, मरीज़ को जनवरी 2021 में, पेट के दाहिने निचले हिस्से में [RLQ] दर्द हुआ, जिसमें सामान्य दवाओं से आराम मिल गया। मगर, ढाई महीने बाद फिर से दर्द हुआ। इसलिए, बार-बार होने वाले एपेंडिसाइटिस का निदान किया गया

केस का सारांश: बार-बार होने वाले एपेंडिसाइटिस के इस केस का उपचार अप्रैल से अगस्त 2021 तक, केन्द्रीय होम्योपैथी अनुसंधान परिषद [CCRH] के अंतर्गत, राष्ट्रीय होम्योपैथी मानसिक स्वास्थ्य अनुसंधान संस्थान, कोट्टायम, केरल में होम्योपैथिक दवा आईरिस टेनैक्स [Iris-t] से किया गया। इस केस में मरीज़ ने पेट के दाहिने निचले हिस्से (RLQ) में पीड़ा और छूने पर हल्के से मध्यम दर्द के साथ प्रस्तुत किया। होम्योपैथिक उपचार शुरू करने के दूसरे सप्ताह में एपेंडिसाइटिस के लक्षणों में स्पष्ट रूप से सुधार हुआ। HOM-CASE दिशानिर्देशों के अनुसार होम्योपैथिक दवा के चिकित्सकीय परिणाम के गुणारोपण की संभावना का मूल्यांकन, होम्योपैथी के संशोधित नारन्जो मानदंड, जो कि एक कारण गुणारोपण स्कोर है, से किया गया। उपचार के बाद अल्ट्रासोनोग्राफी रिपोर्ट में एपेंडिसाइटिस का कोई भी साक्ष्य नहीं पाया गया। +8/13 के MONARCH स्कोर से निर्धारित दवा और उपचार के परिणाम के बीच संभावित कारण गुणारोपण का संकेत मिलता है। वर्तमान केस की रिपोर्ट एपेंडिक्स पैथोलॉजी के मामलों में होम्योपैथिक दवा आईरिस-टी की संभावित उपयोगिता को दर्शाती है।

Appendicitis recurrente tratada con el medicamento homeopático *Iris tenax 30C*: Un informe de caso

Introducción: Las variantes no agudas de la apendicitis incluyen apendicitis recurrente, subaguda y crónica, que rara vez se diagnostican y siguen siendo objeto de informes de casos. El diagnóstico es complejo y se basa en la historia, el examen clínico y la ecografía o TC. A diferencia de la variedad aguda, una emergencia quirúrgica, estos casos no requieren cirugía inmediata. En el presente caso, el paciente presentó dolor en el cuadrante inferior derecho [RLQ] del abdomen en enero de 2021, que se alivió con medicamentos convencionales. Sin embargo, el dolor reapareció después de dos meses y medio. Por lo tanto, se sugiere el diagnóstico de apendicitis recurrente.

Resumen del caso: Este caso de apendicitis recurrente fue tratado de abril a agosto de 2021 en el Instituto Nacional de Investigación de Homeopatía en Salud Mental Kottayam Kerala, bajo el Consejo Central de Investigación en Homeopatía [CCRH] India con el medicamento homeopático *Iris-Tenax [Iris-t]*. Este caso se presentó con dolor en el cuadrante inferior derecho (RLQ) del abdomen con sensibilidad leve a moderada. Hubo una marcada mejoría en los síntomas de apendicitis en la segunda semana de comenzar el tratamiento homeopático. Los criterios modificados de Naranjo para la homeopatía, una puntuación del inventario de atribución causal, evaluaron la probabilidad de atribución del resultado clínico a la medicina homeopática según las pautas de HOM-CASE. El informe de la ecografía no mostró evidencia de apendicitis después del tratamiento. La puntuación MONARCH de +8/13 indicó una probable relación causal entre el medicamento prescrito y el resultado del tratamiento. El presente informe de caso muestra la posible utilidad del medicamento homeopático *Iris-t* en casos con una patología del apéndice.

势 法 物 Iris tenax 30C 治 复 性 尾 炎：一 例 报 告

引言：尾炎的非急性 异包括复 性、 急性和慢性 尾炎，这些疾病很少被 断出来，仍然是病例报告的主 。 断是复 的，基于病史、 床 查和超声心动 或CT。与急性类型的外科急 不同，这些病例不需要立即手术。在本例中，患者于2021年1月出 腹部右下象限疼痛，通过常 物 解。然而，疼痛在两个半月后复 。因此，建 对复 性 尾炎 行 断。

病例摘要：本例复 性 尾炎于2021年4月至8月在印度中央 势 法研究委 会下属的喀拉拉邦科特 姆(Kottayam) 精神 生国家 势 法研究所接受了 势 法 物Iris Tenax[Iris-t]的治 。 病例表 腹部右下象限疼痛，伴 有 度至中度压痛。在 始 势 法治 的第二周， 尾炎的症状有了明 的改善。改良的Naranjo 势 法 准是 一种因果归因清单 分，根据HOM-CASE指南 估了将 床 果归因于 势 法 物的可能性。超声 查报告 示治 后没有 尾炎的迹象。MONARCH 分 +8/13表明处方 与治 果之 可能存在因果 系。本病例报告 示了 势 法 物Iris-t在 尾病理病例中的可能作用。